

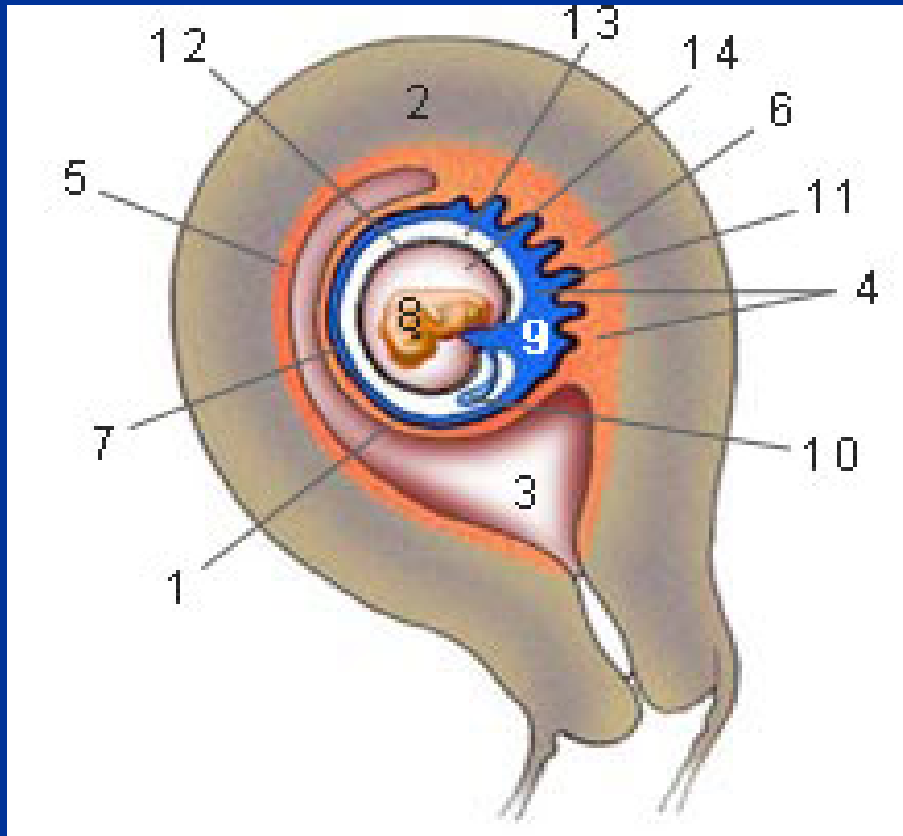
*Ecografia del primo trimestre:
istruzione per l'uso*

Padova, 6 Marzo 2009

**“ Annessi fetali, ovaie,
utero ”**

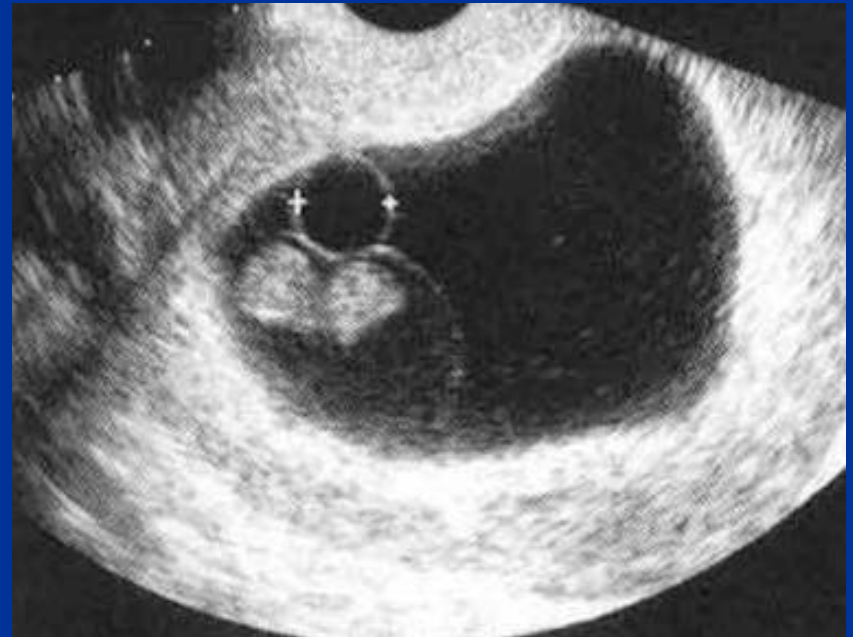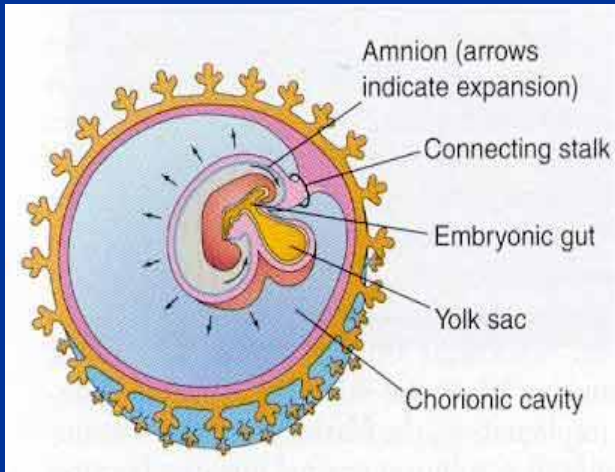
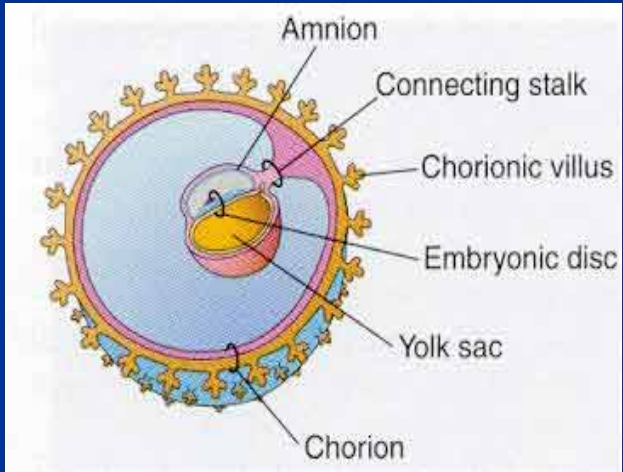
Silvia Narne

Embriologia degli annessi

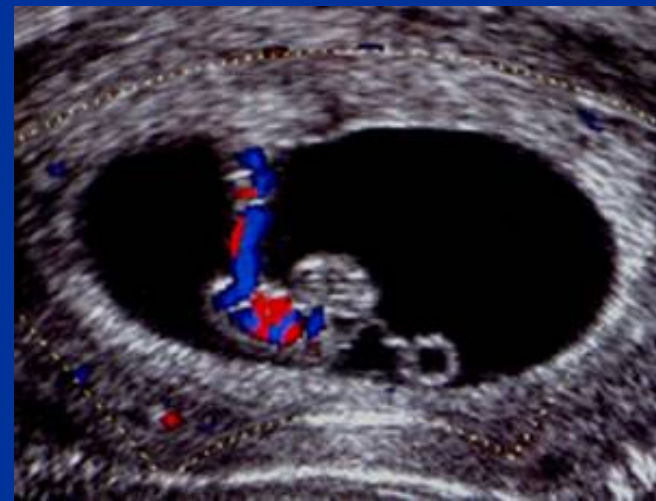
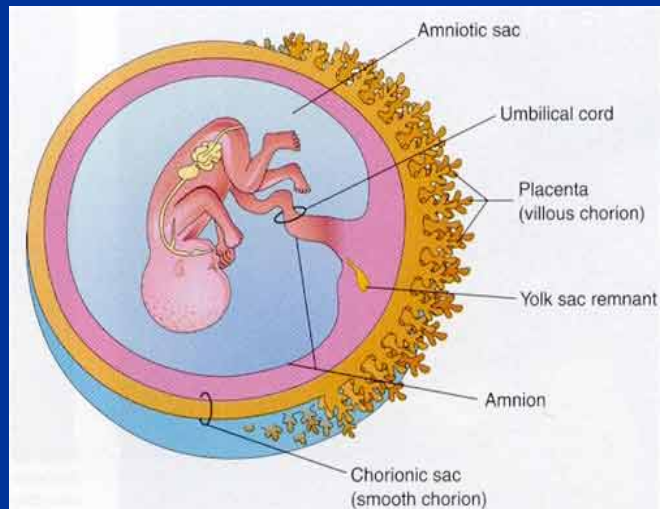
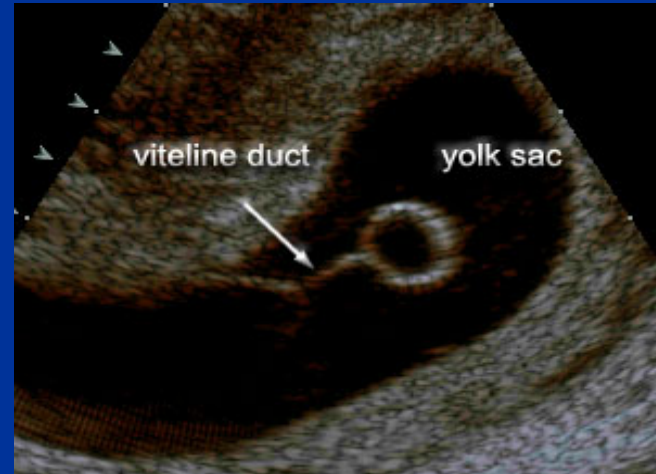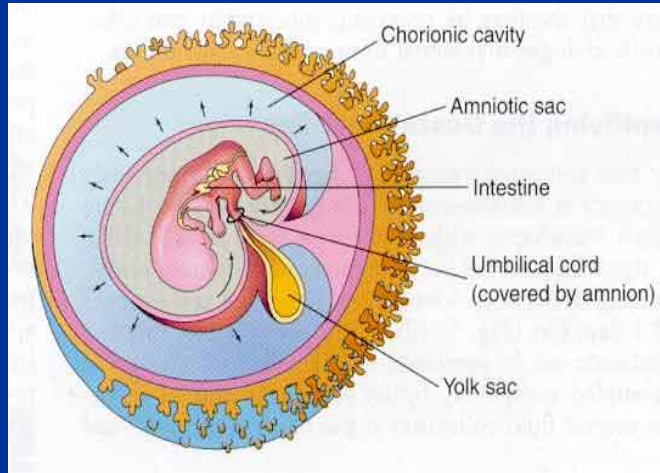


- 1 decidua capsulare**
- 2 parete uterina**
- 3 cavità uterina**
- 4 placenta**
- 5 decidua parietale**
- 6 decidua basale**
- 7 corion laeve**
- 8 embrione**
- 10 sacco vitellino**
- 11 corion frondosum**
- 12 amnios**
- 13 cavità corionica**
- 14 cavità amniotica**

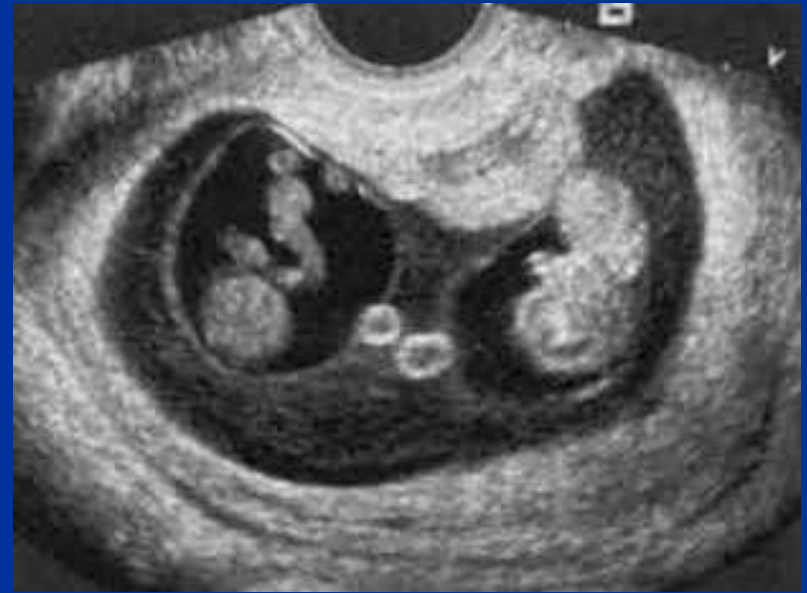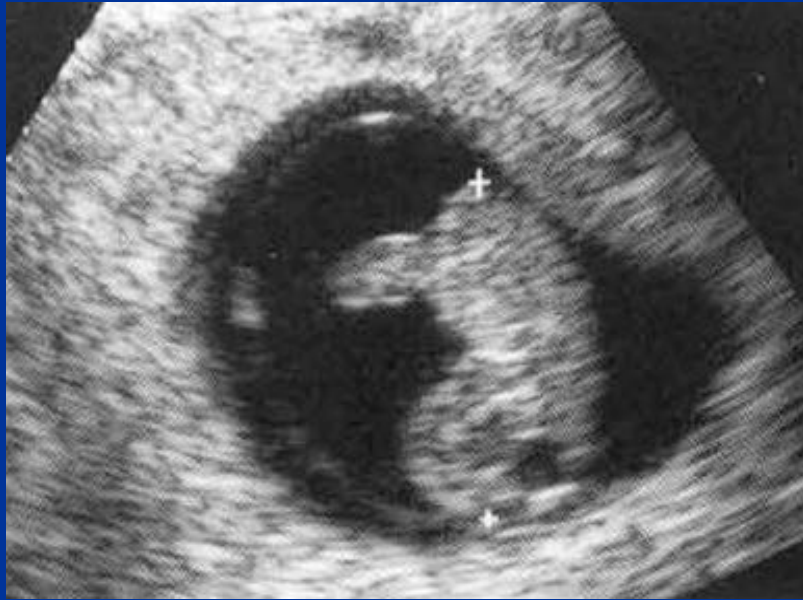Annessi



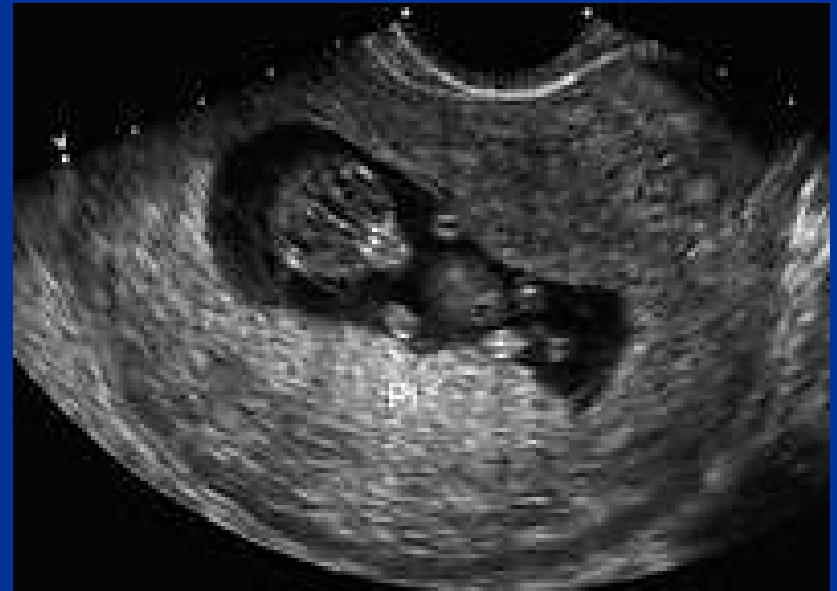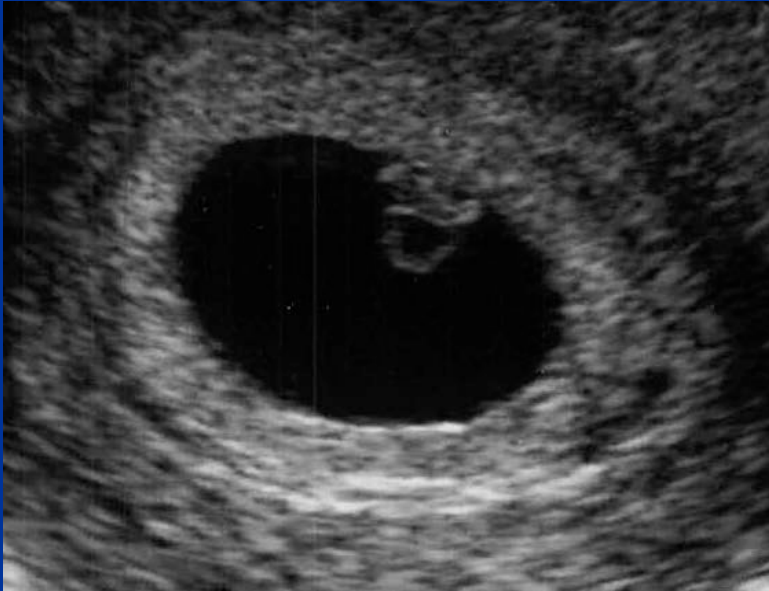Annessi



Amnios

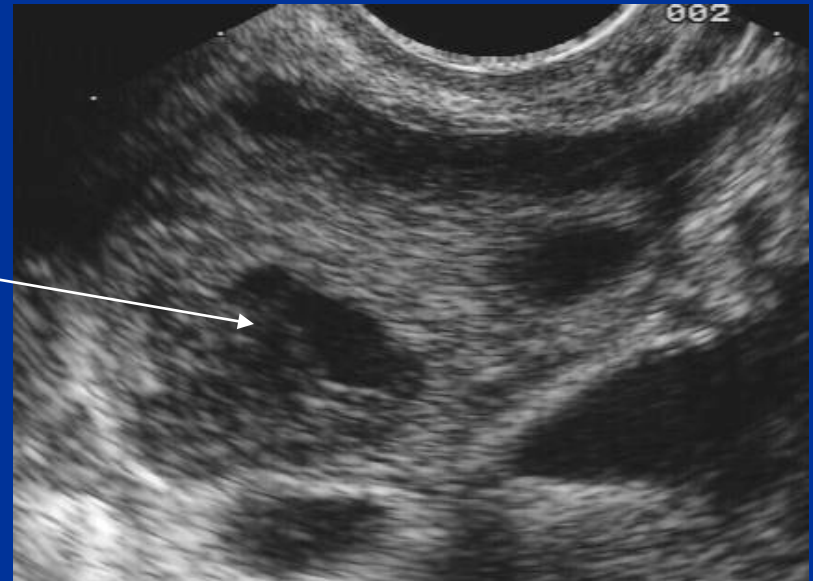
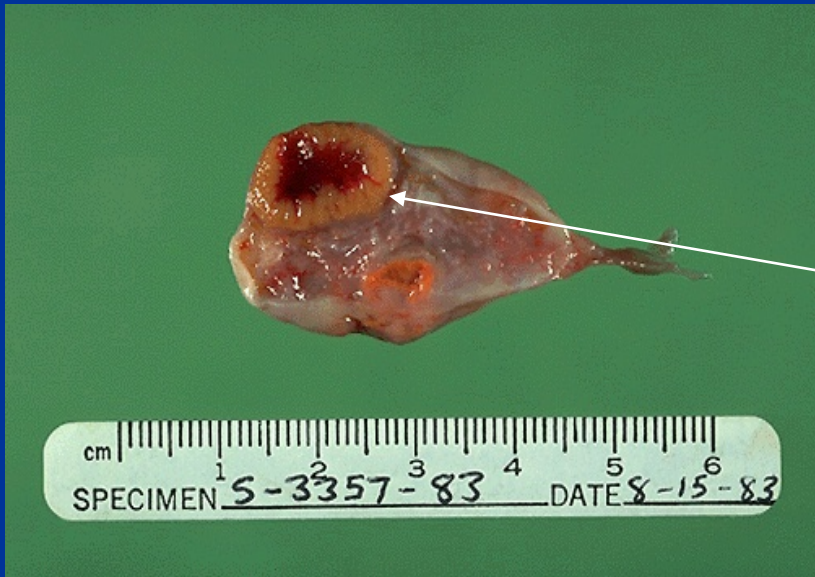

Corion e Placenta

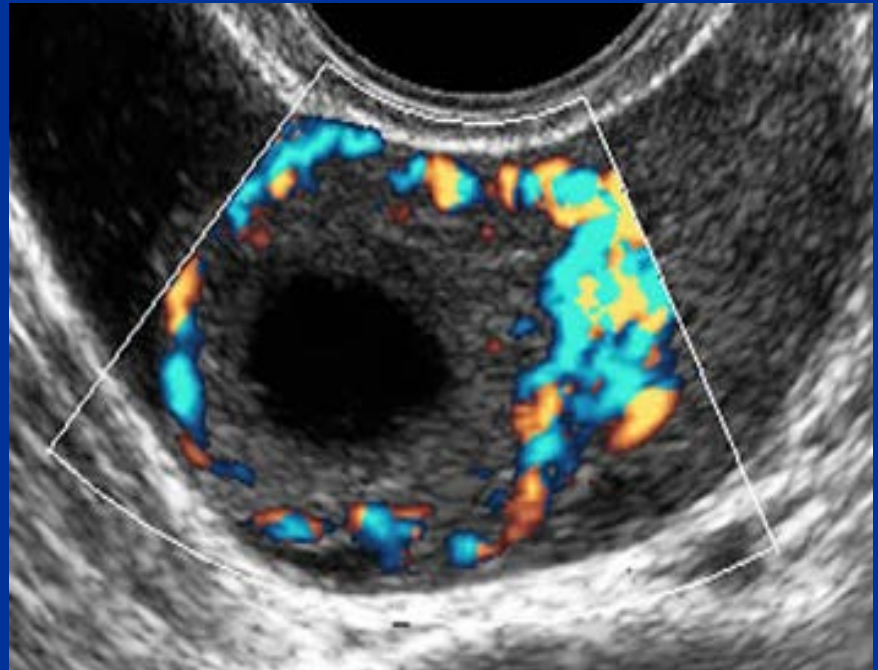
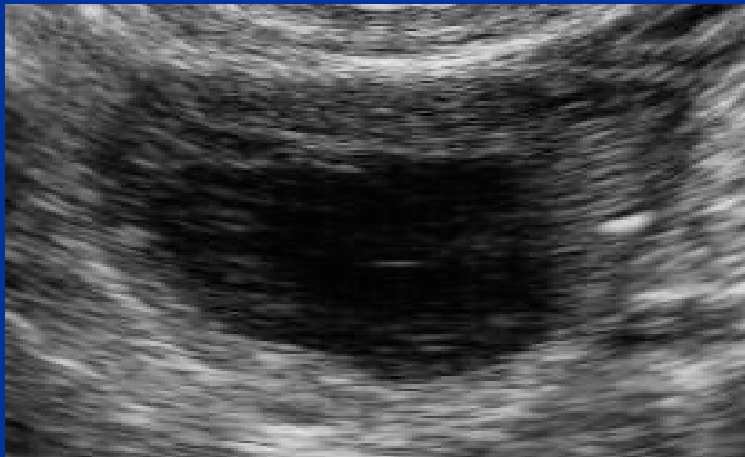
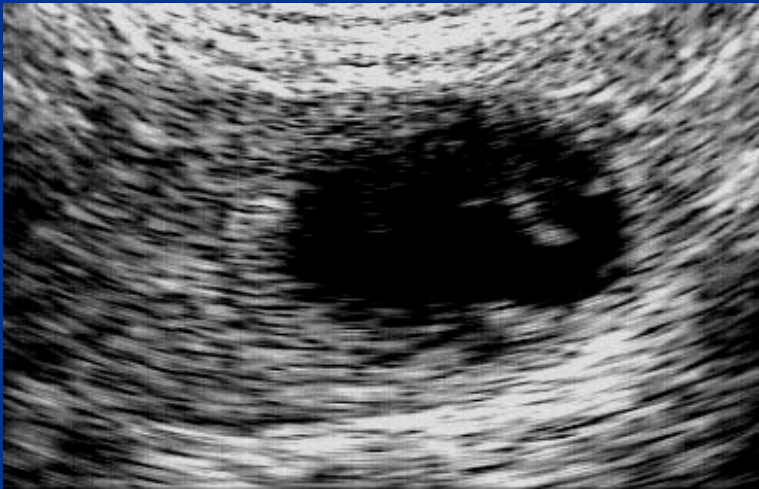
Ovaio

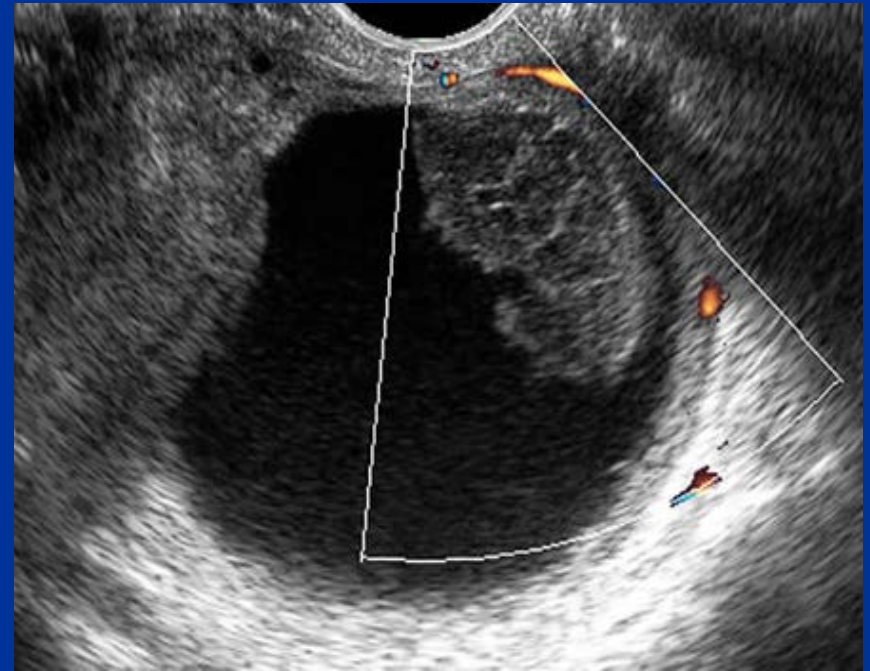
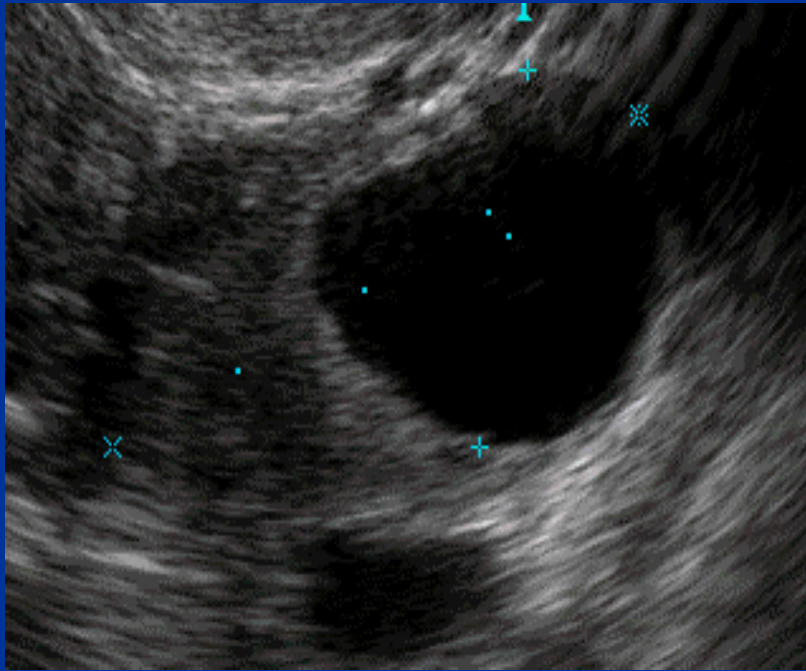
Corpo Luteo



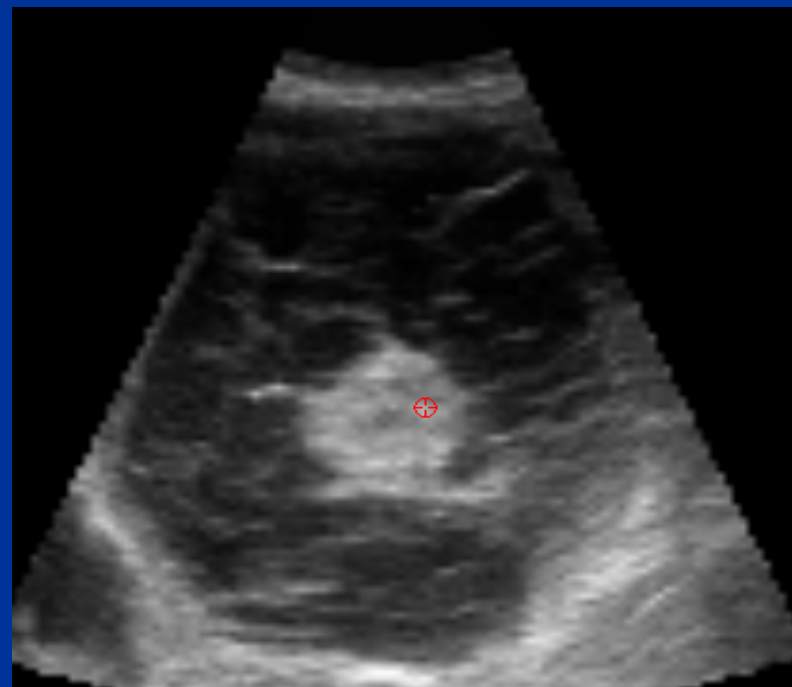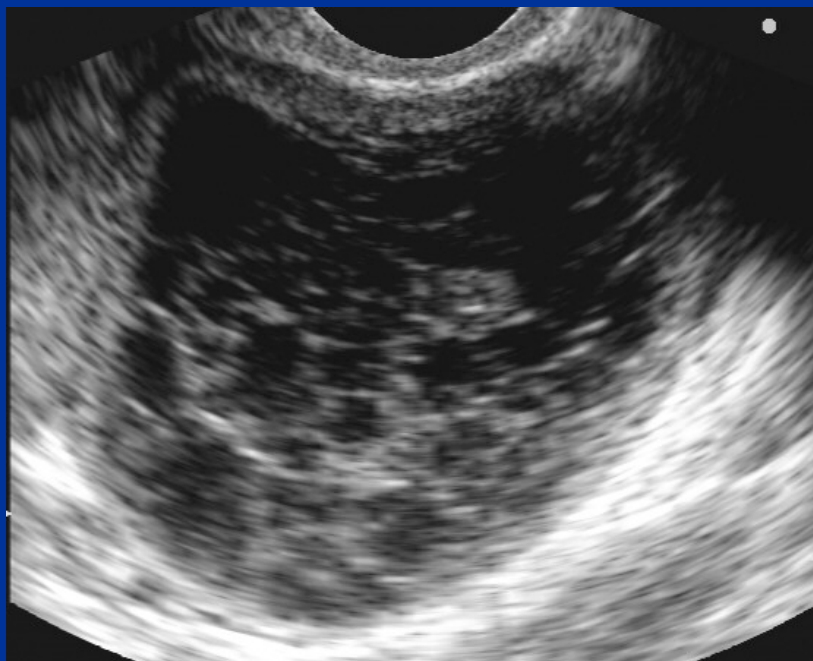Corpo Luteo



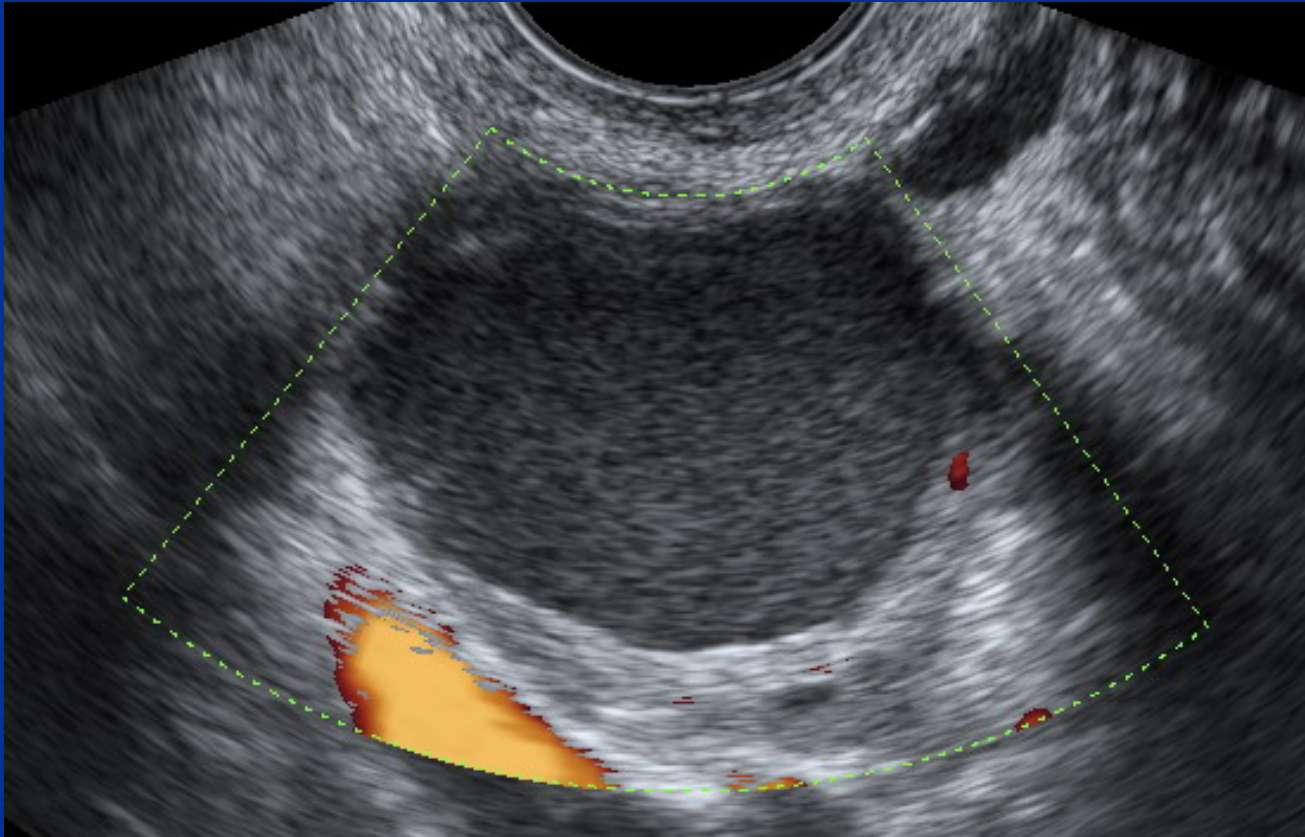
Corpo Luteo Cistico



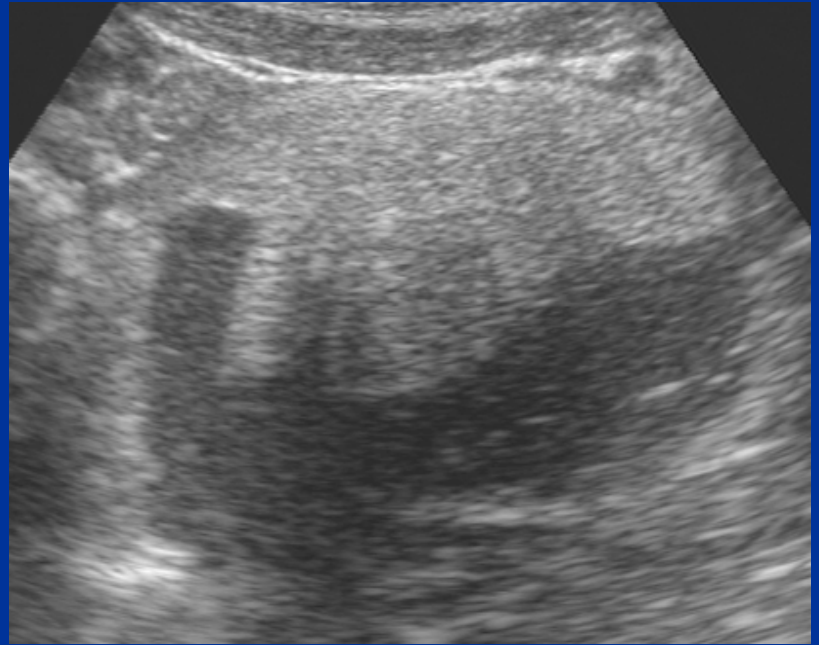
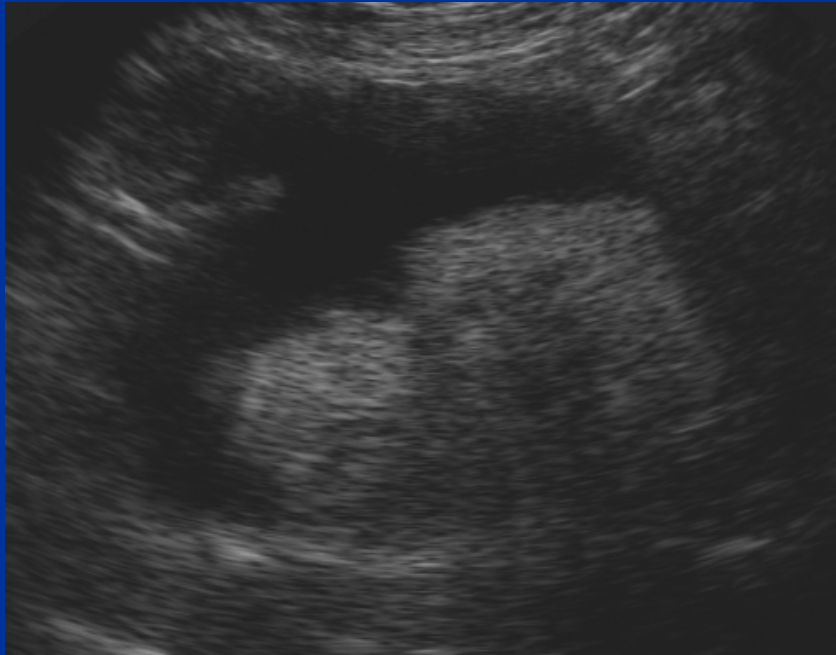Corpo Luteo Emorragico



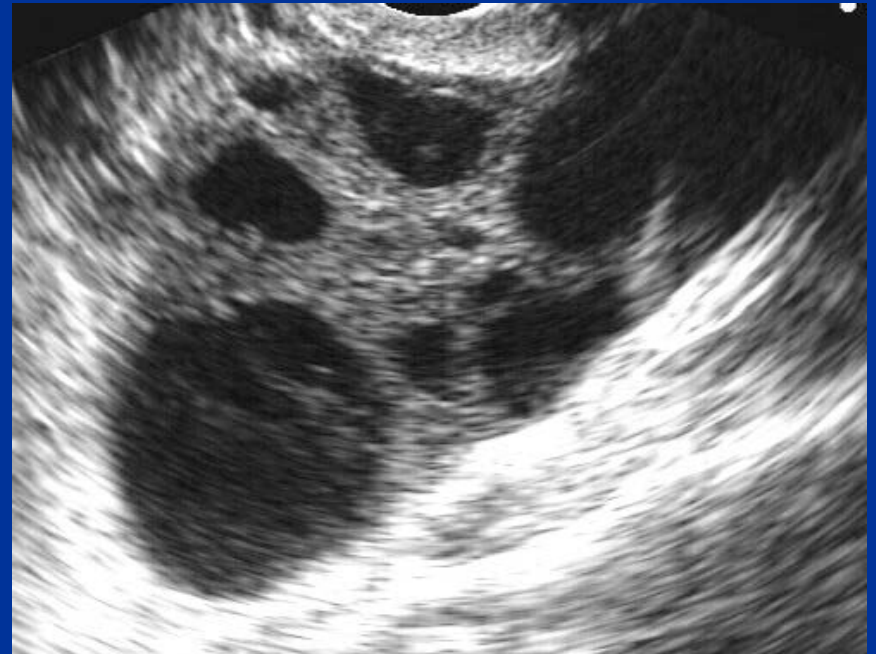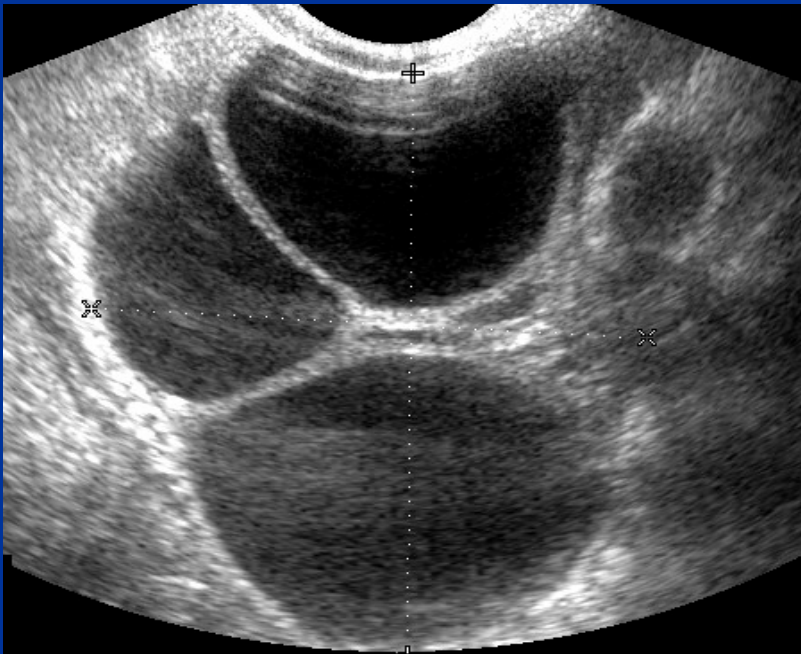
Endometrioma



Cisti Dermoidi

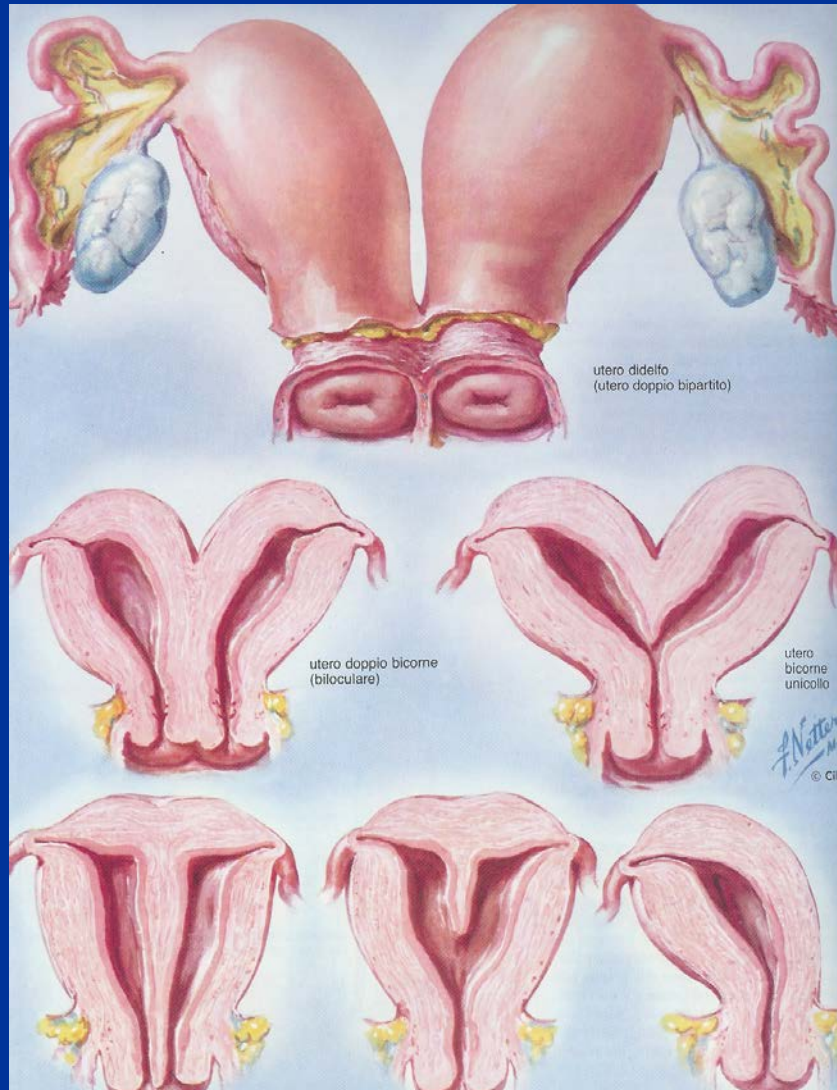


Iperstimolazione ovarica



**Utero:
Malformazioni mulleriane
Fibromi**

Malformazioni Mülleriane



Utero didelfo

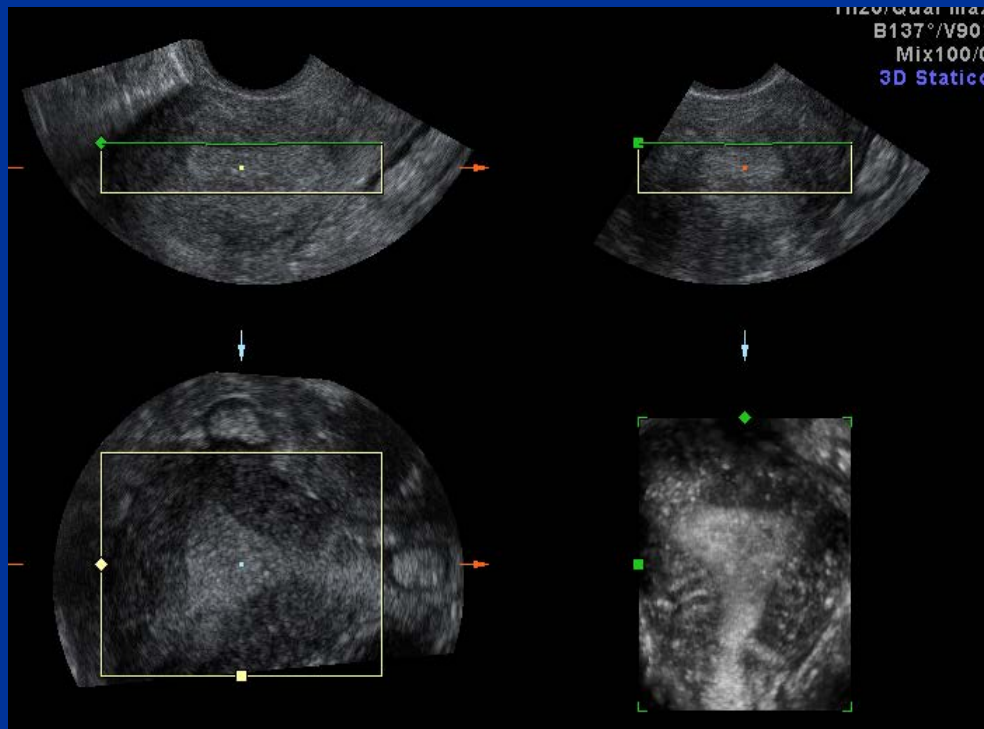Utero
bicornie
bicolle

Utero
bicornie
unicolle

Utero
setto

Utero
unicorno

Malformazioni Mülleriane ed ecografia

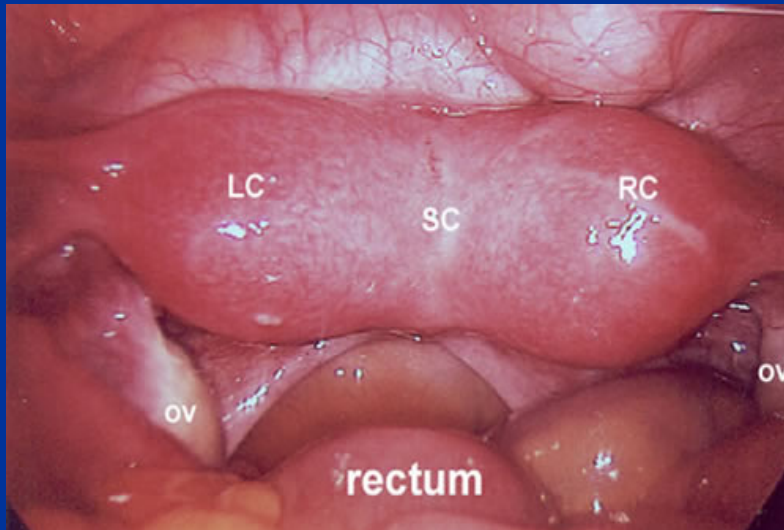
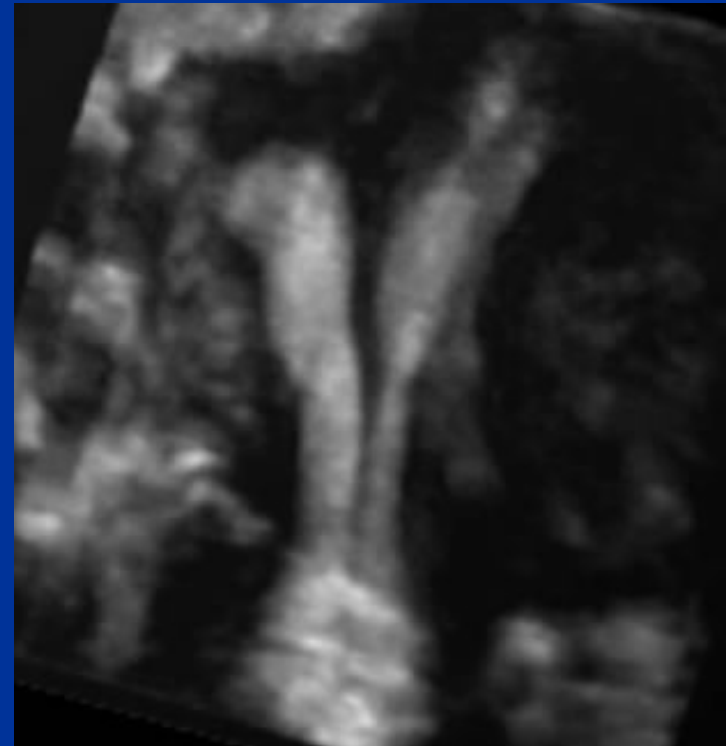
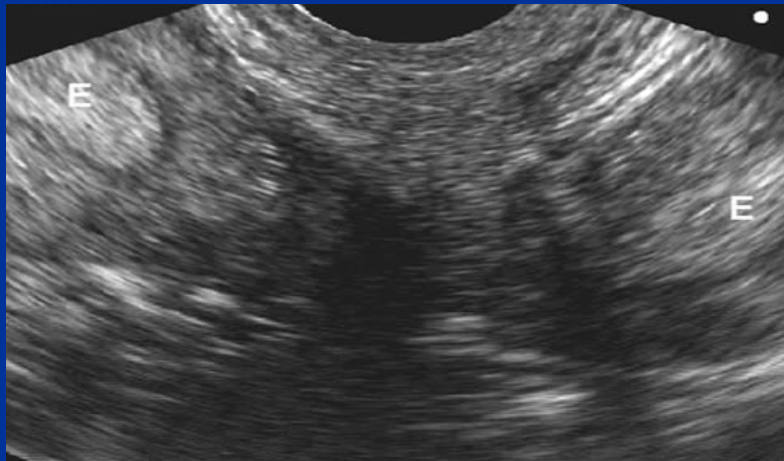

Aspetti diagnostici:

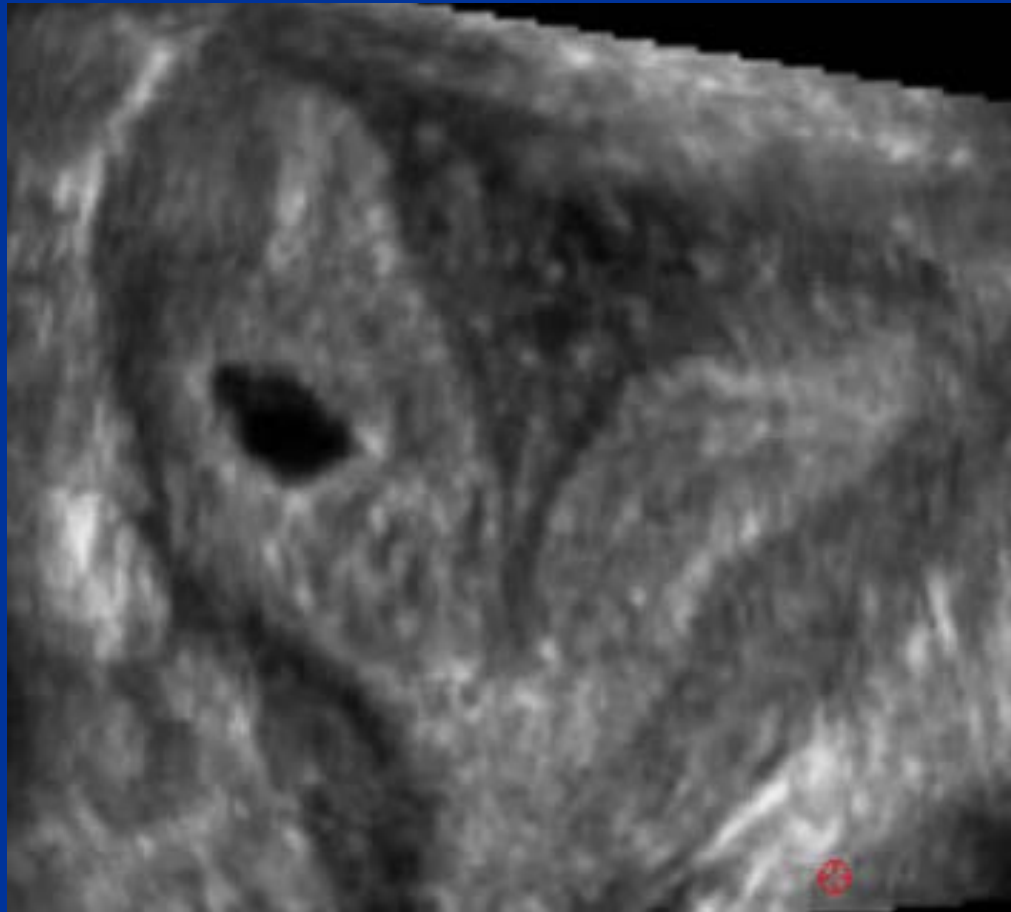
- Diametro trasverso utero
- Contorni
- Morfologia cavità (linea endometriale)

SEZIONE CORONALE

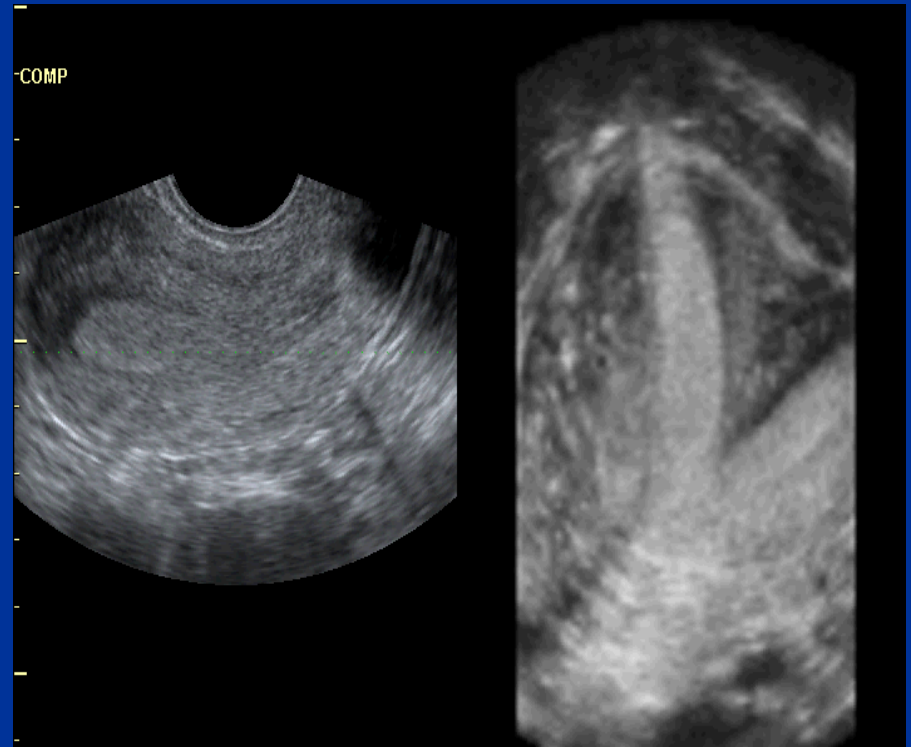
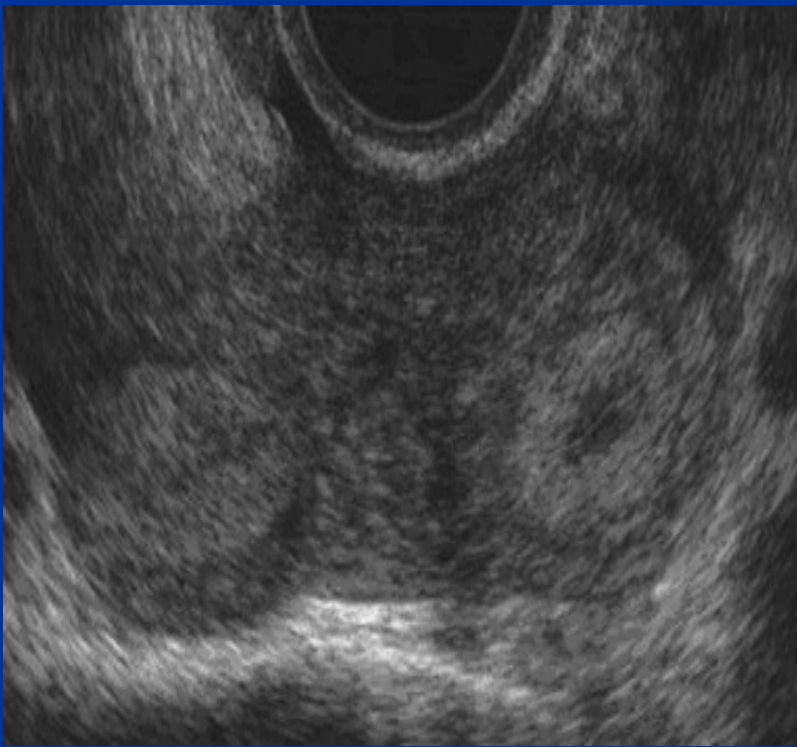
Utero bicornis



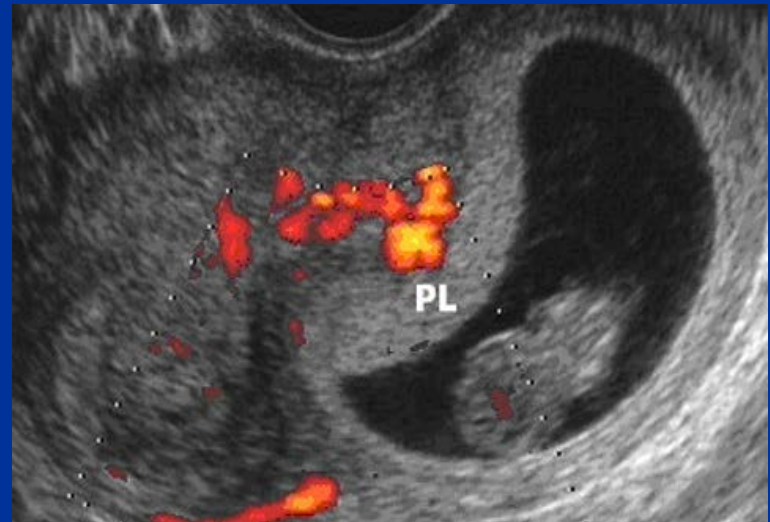
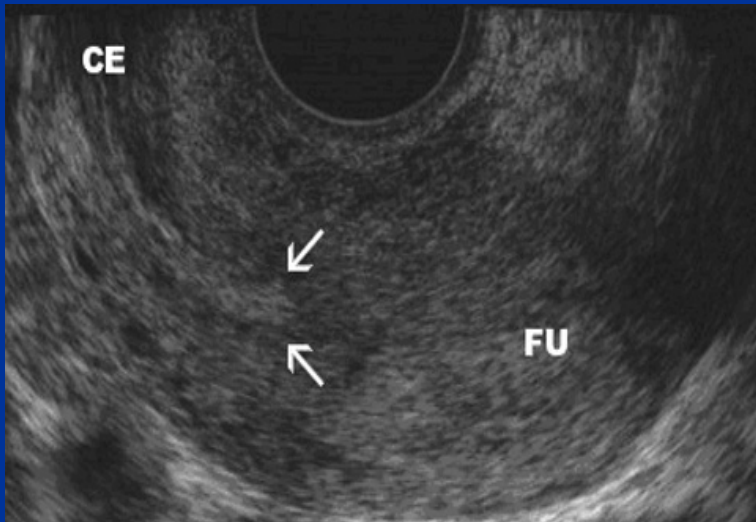
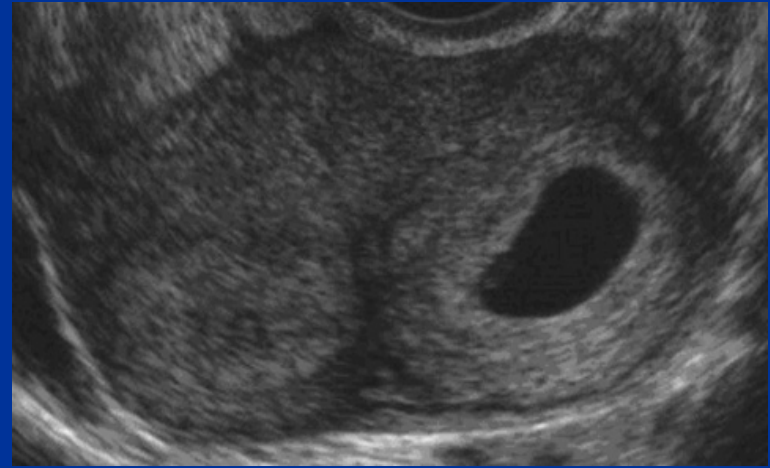
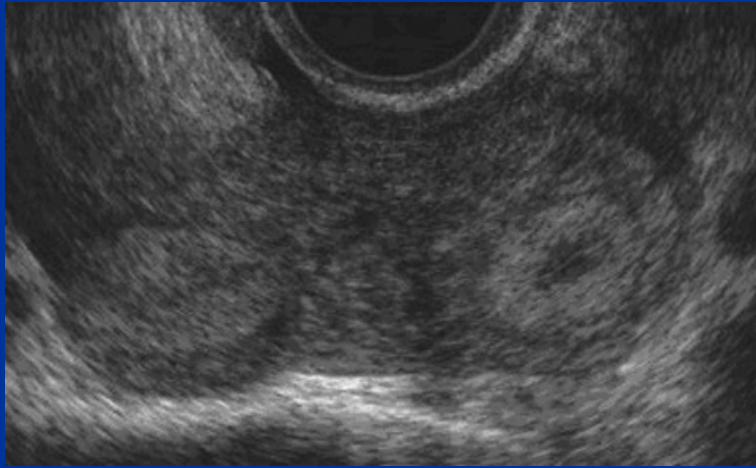
Gravidanza in utero bicorne



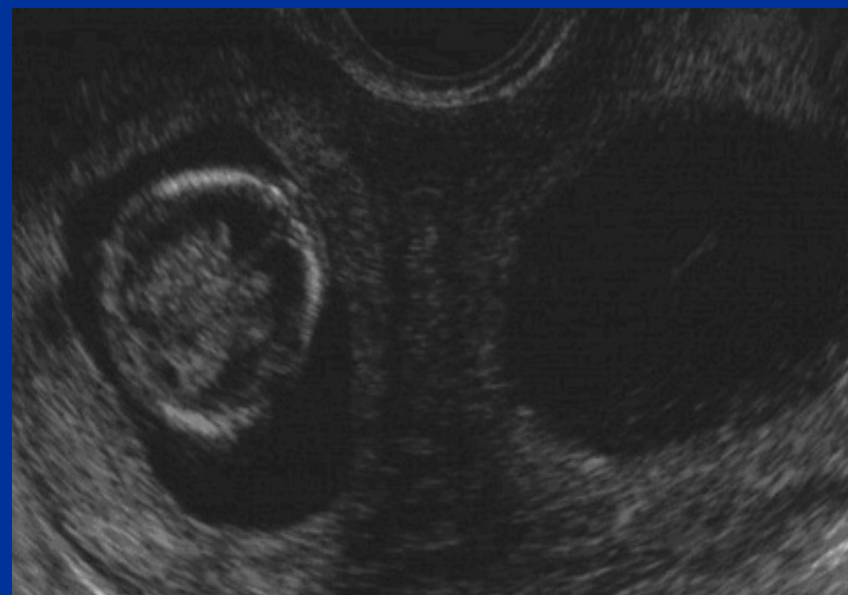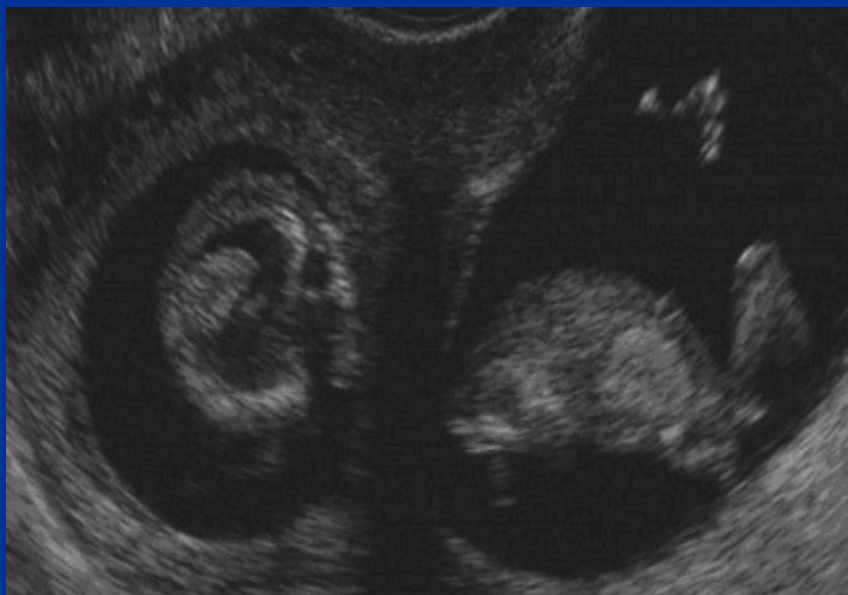Utero setto



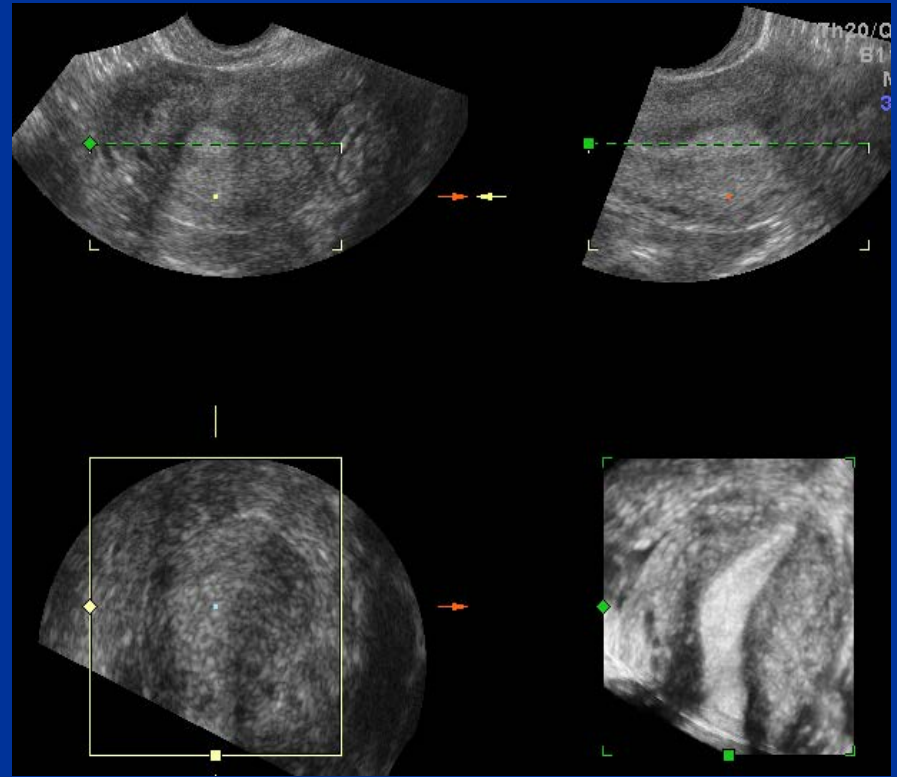
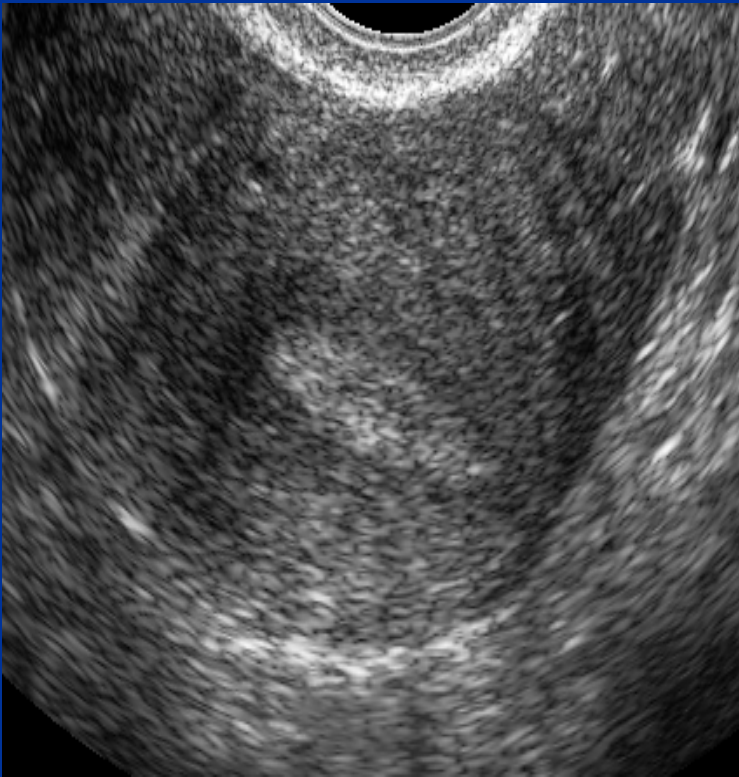
Gravidanza in utero setto



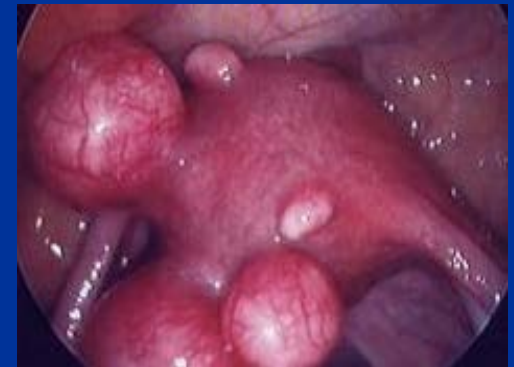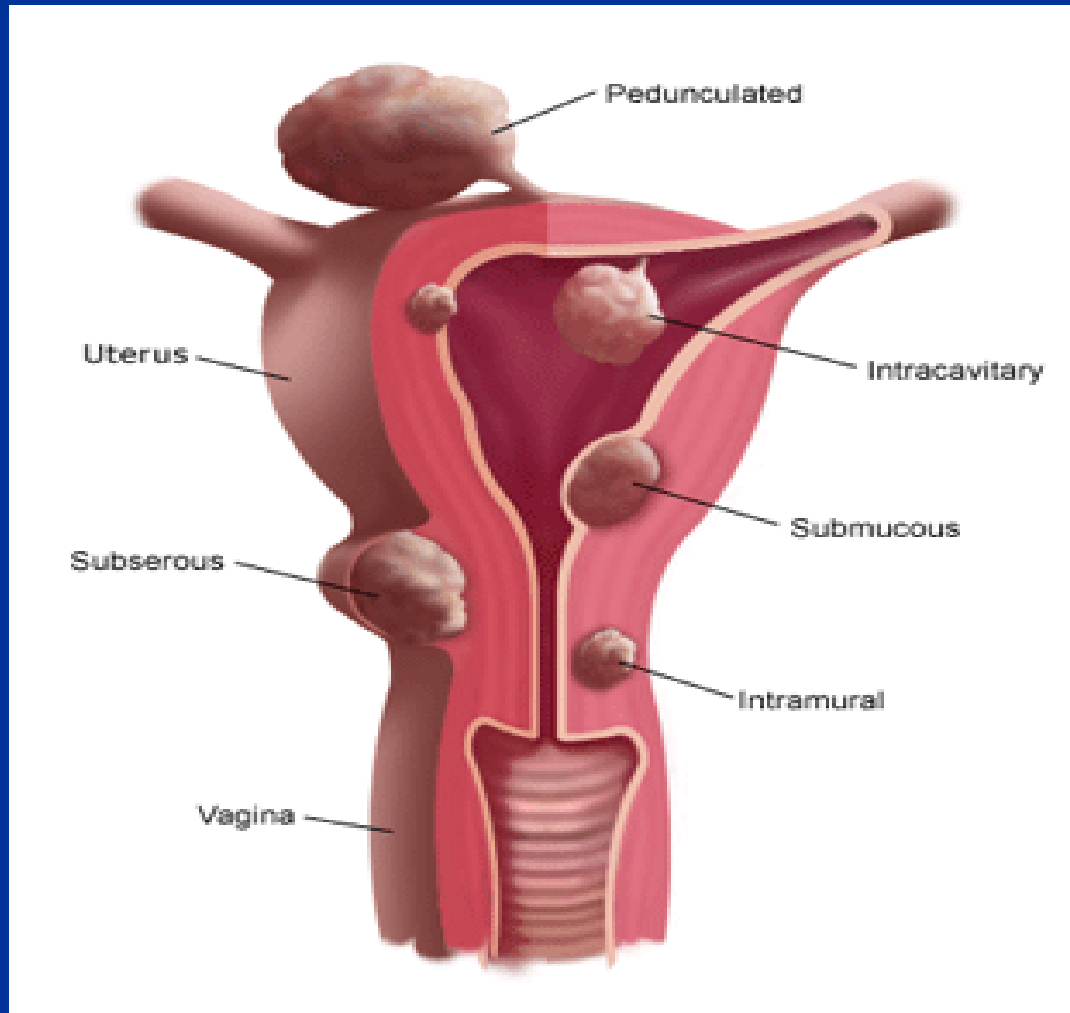
Gravidanza in utero setto



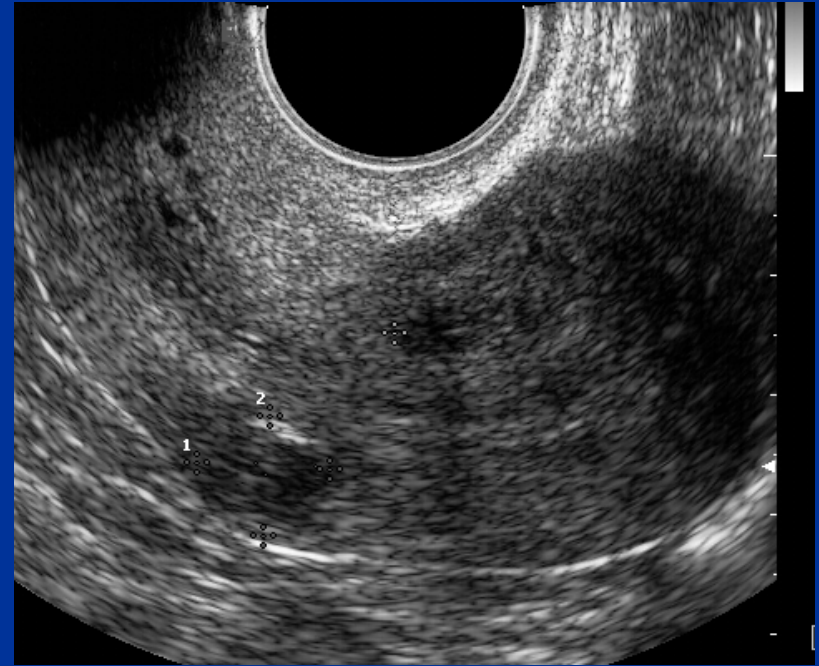
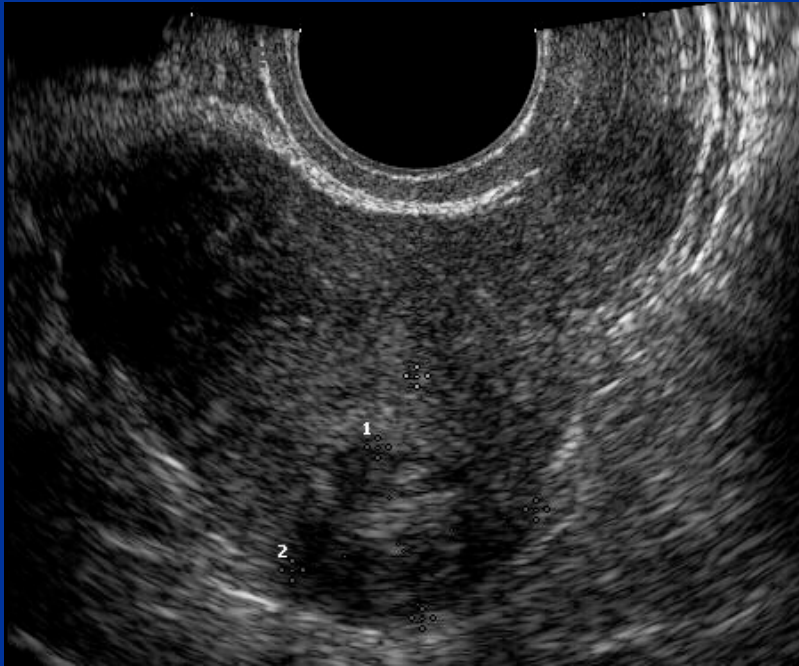Utero unicorne



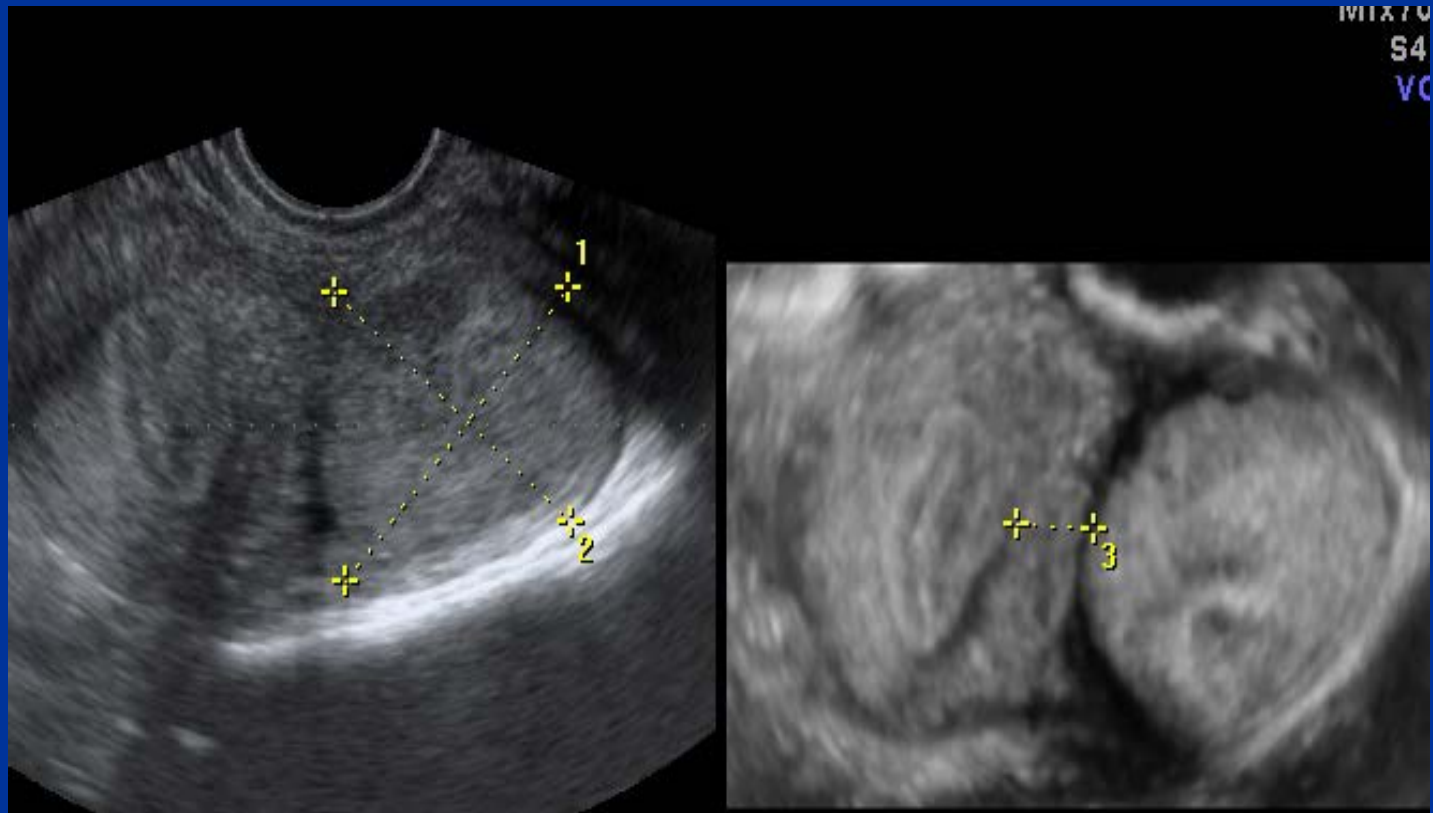Fibromi



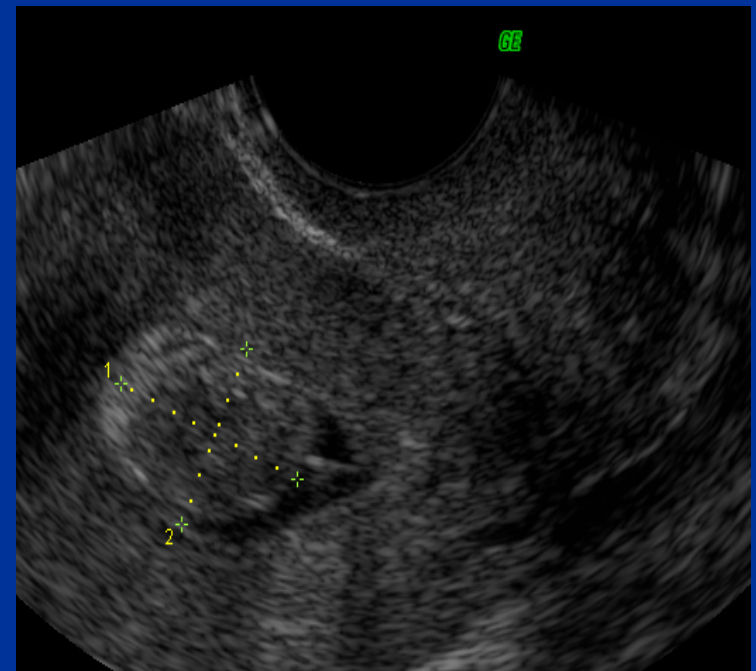
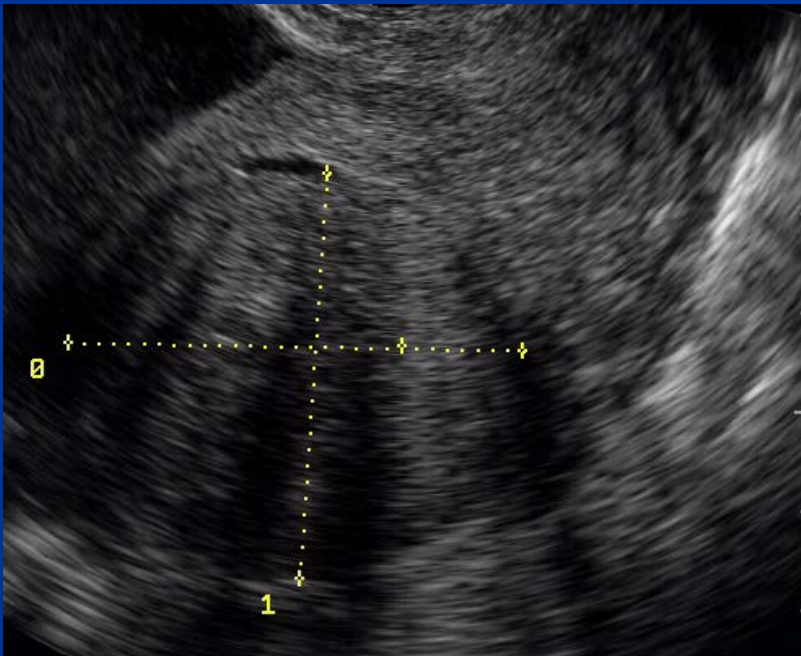
Fibromi



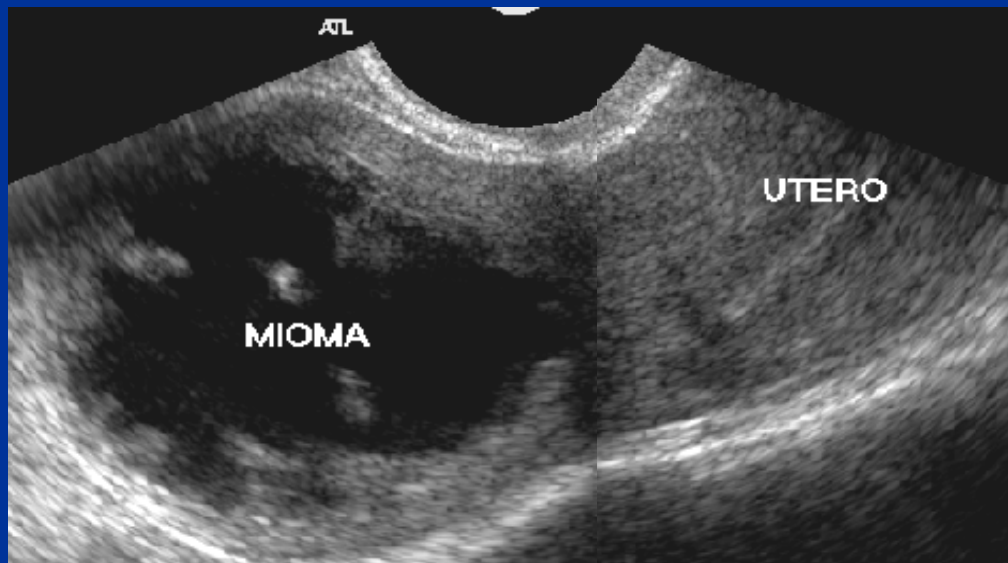
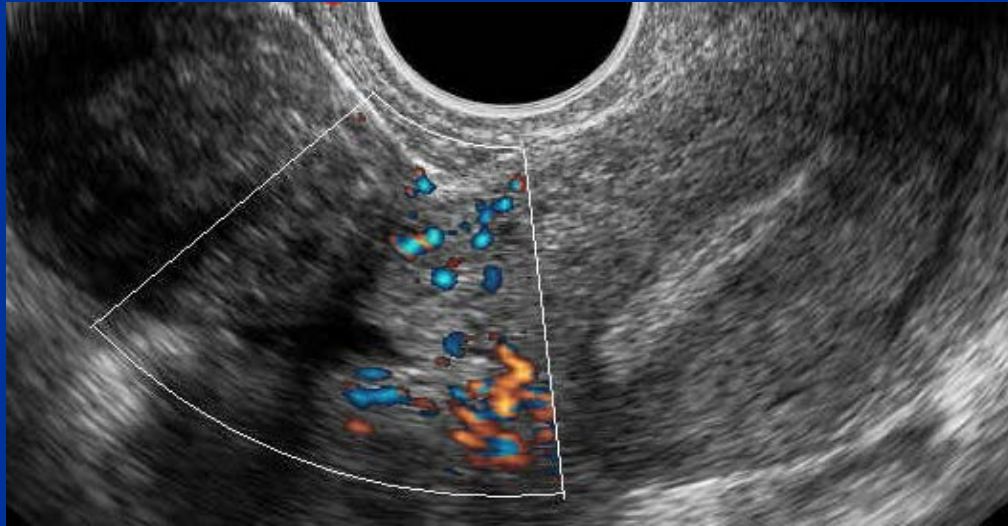
Fibroma intramurale- sottosieroso



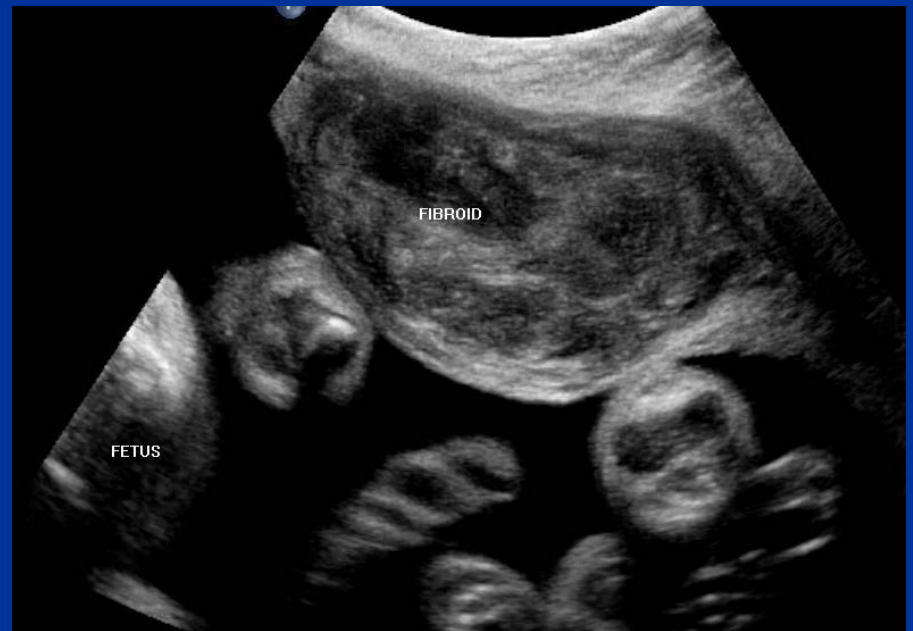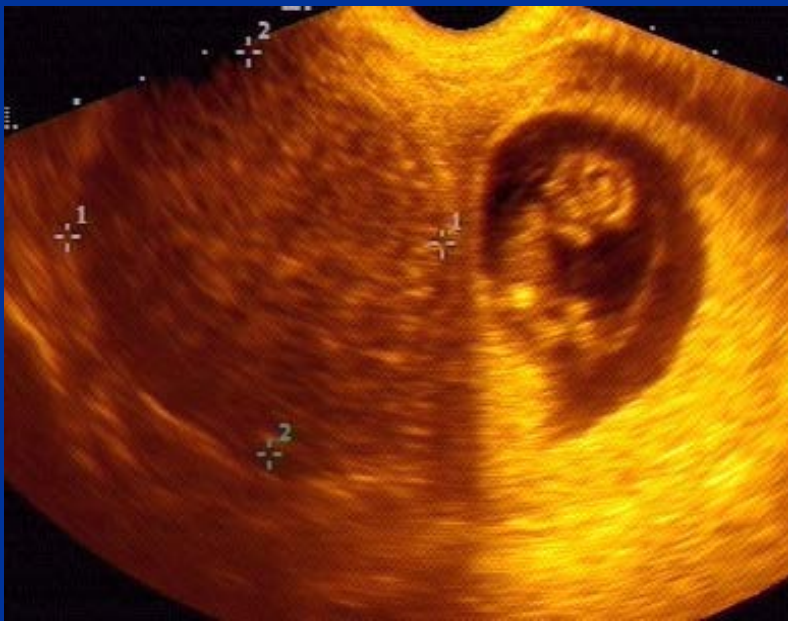Fibroma intramurale- sottomucoso



Fibroma pedunculato



Fibromi in gravidanza





Gravidanza ectopica