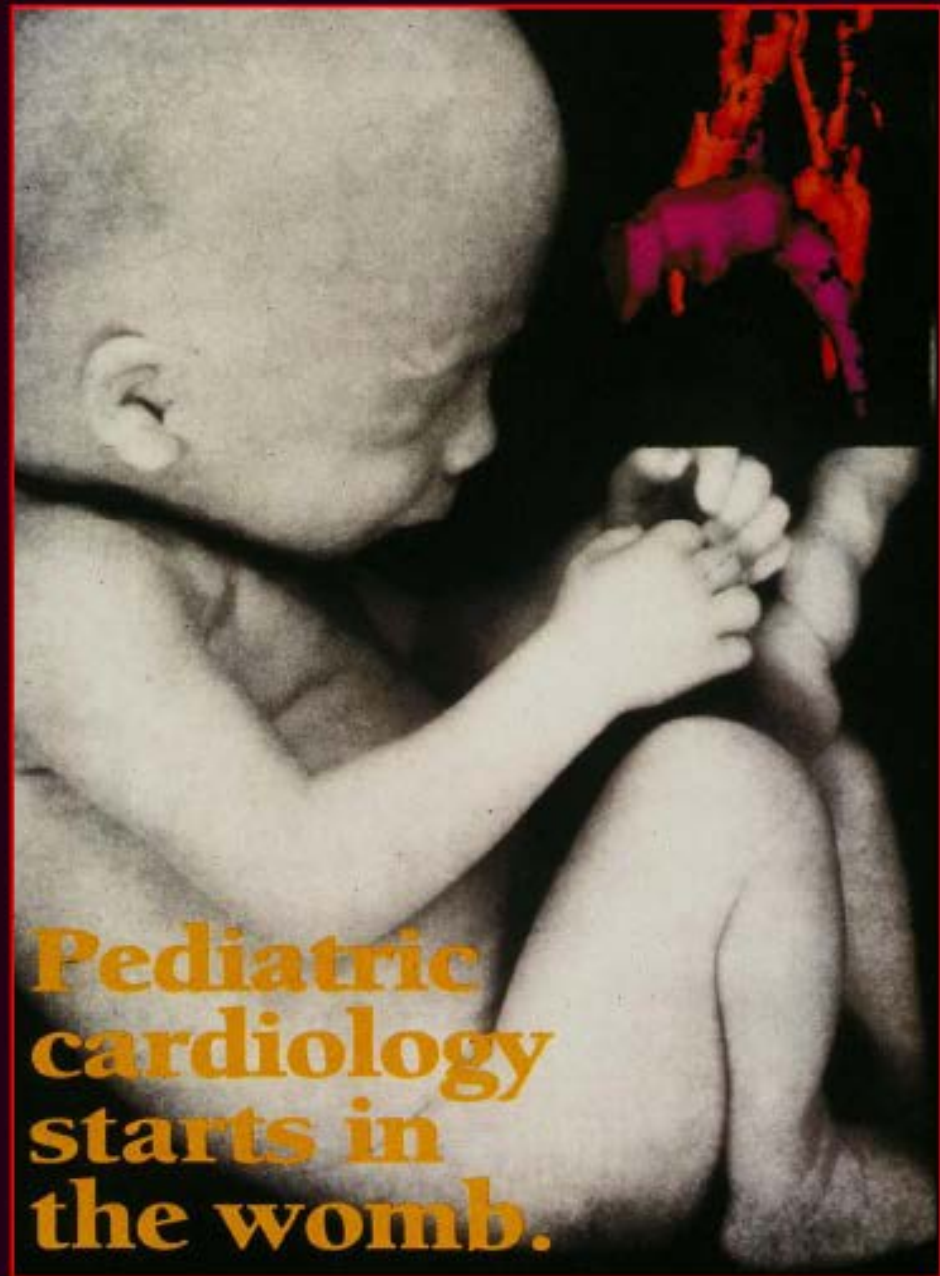
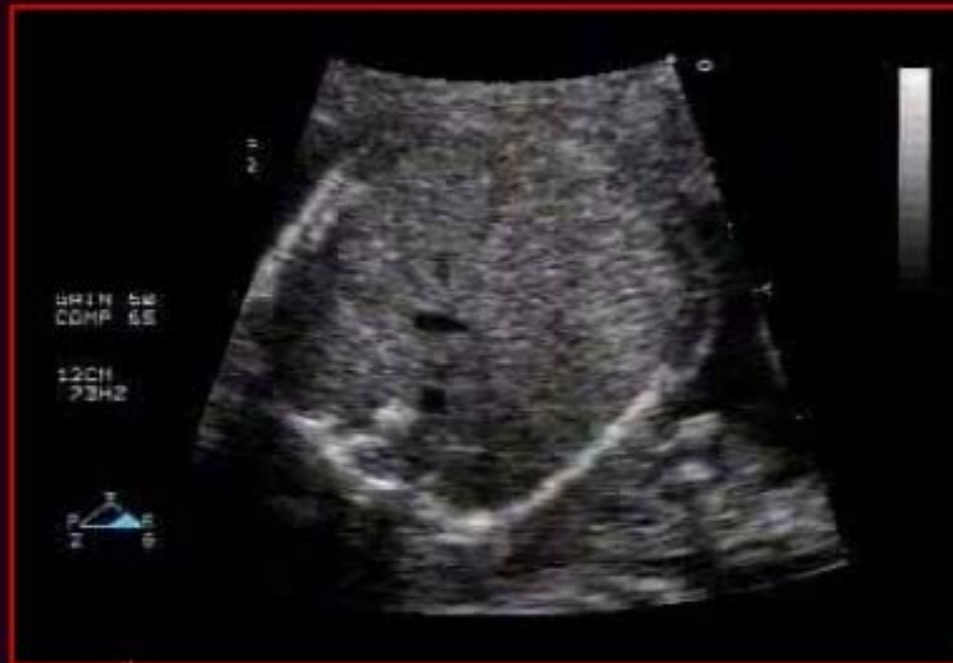

Prenatal Diagnosis Relies Upon Prenatal Detection



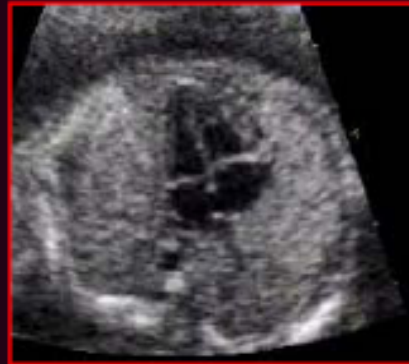**Pediatric
cardiology
starts in
the womb.**

Screening Anatomic Survey What is Important?



Distinguish
Normal vs Abnormal vs Possibly Abnormal

Formal Fetal Echocardiography What is Important?



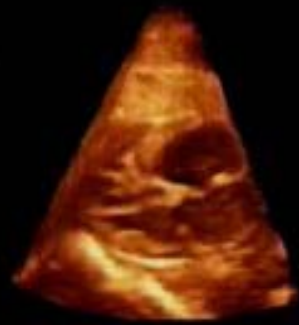Fetal echocardiographic screening for congenital heart disease: The importance of the four-chamber view

**Joshua A. Copel, M.D.,* Gianluigi Pilu, M.D., Jacqueline Green, M.S., R.D.M.S.,
John C. Hobbins, M.D., and Charles S. Kleinman, M.D.****

New Haven, Connecticut

The four-chamber view of the heart has been proposed as a screening method for obstetrical sonographers to assess the fetus for the presence of congenital heart disease. We examined the fetuses in 1022 pregnancies and found 74 structurally abnormal hearts. Seventy-one of these (96%) were found to have an abnormality as seen in the four-chamber view. The four-chamber view of the heart had 92% sensitivity and 99.7% specificity in the detection of congenital heart disease. The positive predictive value was 95.8%, and the negative predictive value was 99.4%. We conclude that the four-chamber view may be a useful screen for the presence of congenital heart disease and should be included as a part of all routine obstetric ultrasound examinations. (*AM J OBSTET GYNECOL* 1987;157:648-55.)

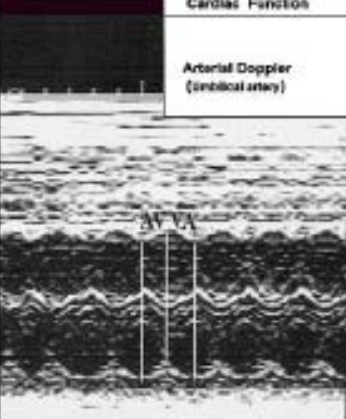
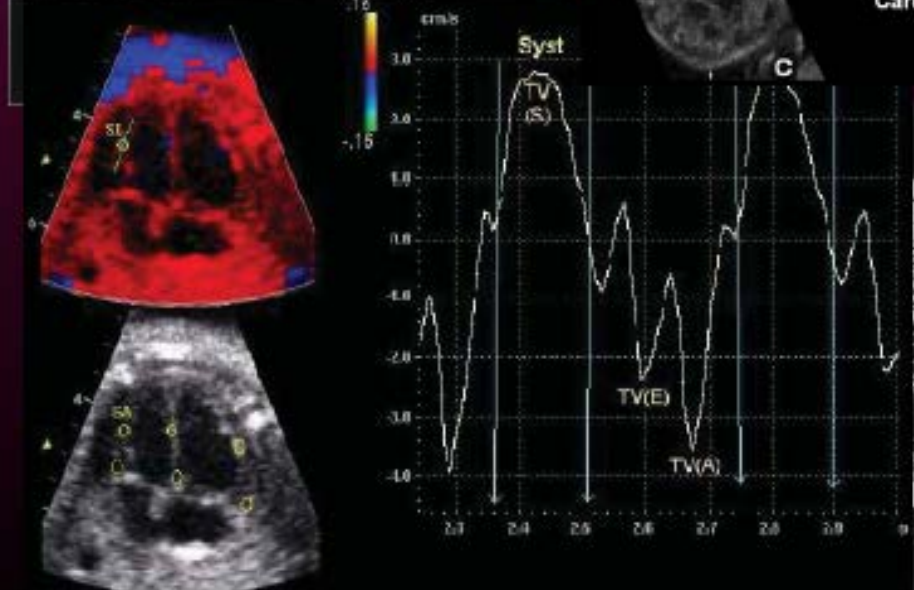
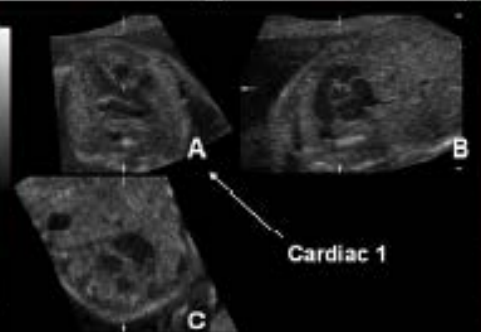
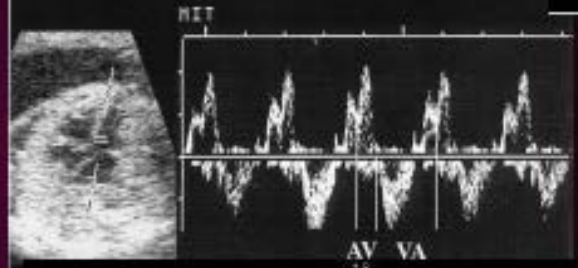
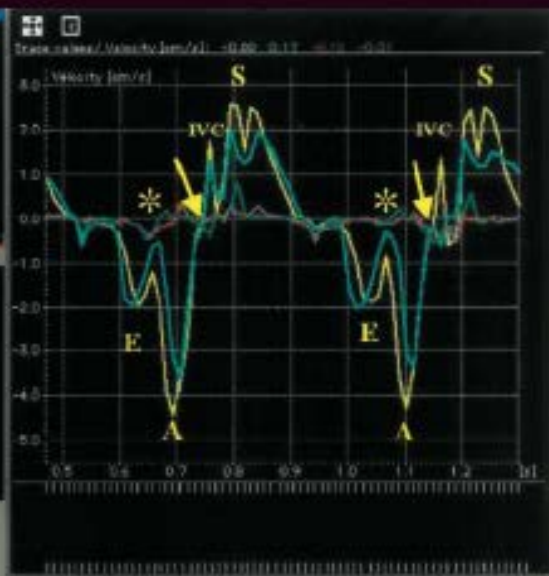
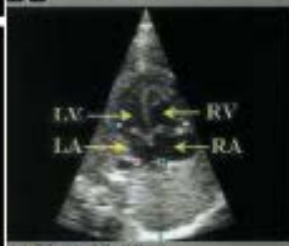
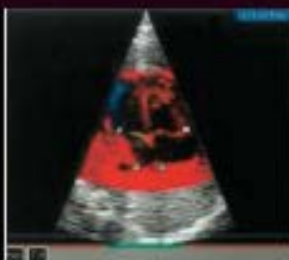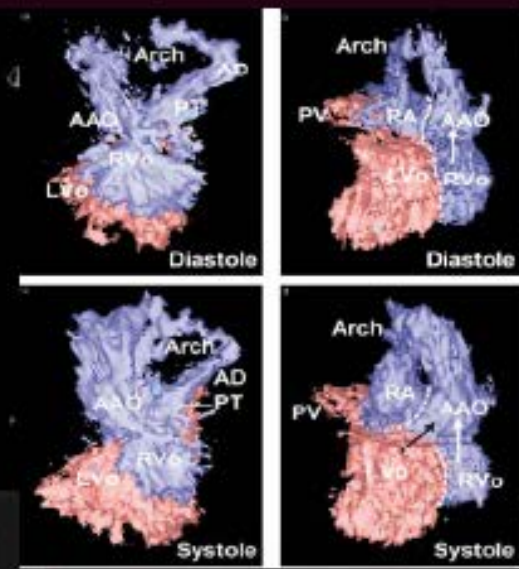
W1: 2.3
 7 MAR 2002
 14:07:48
 4-20-14
 TULA
 FETAL 3D



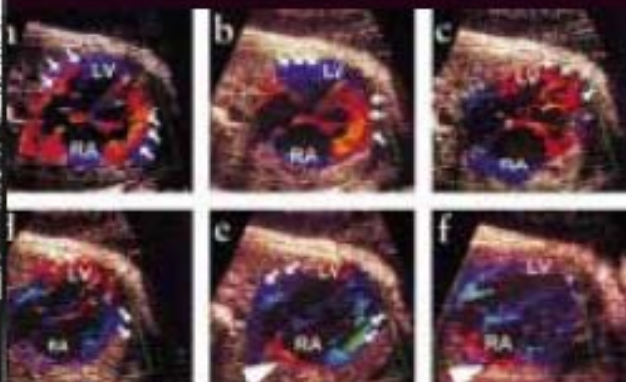
10 11 12 13 14 15 16 17 18 19 20 21 22 23 24 25 26 27 28 29 30 31 32 33 34 35 36 37 38 39 40 41 42 43 44 45 46 47 48 49 50 51 52 53 54 55 56 57 58 59 60 61 62 63 64 65 66 67 68 69 70 71 72 73 74 75 76 77 78 79 80 81 82 83 84 85 86 87 88 89 90 91 92 93 94 95 96 97 98 99 100

20H
 3.30-2

0.07
 0.02
 1 2 3 4 5 6 7 8 9 10 11 12 13 14 15 16 17 18 19 20 21 22 23 24 25 26 27 28 29 30 31 32 33 34 35 36 37 38 39 40 41 42 43 44 45 46 47 48 49 50 51 52 53 54 55 56 57 58 59 60 61 62 63 64 65 66 67 68 69 70 71 72 73 74 75 76 77 78 79 80 81 82 83 84 85 86 87 88 89 90 91 92 93 94 95 96 97 98 99 100

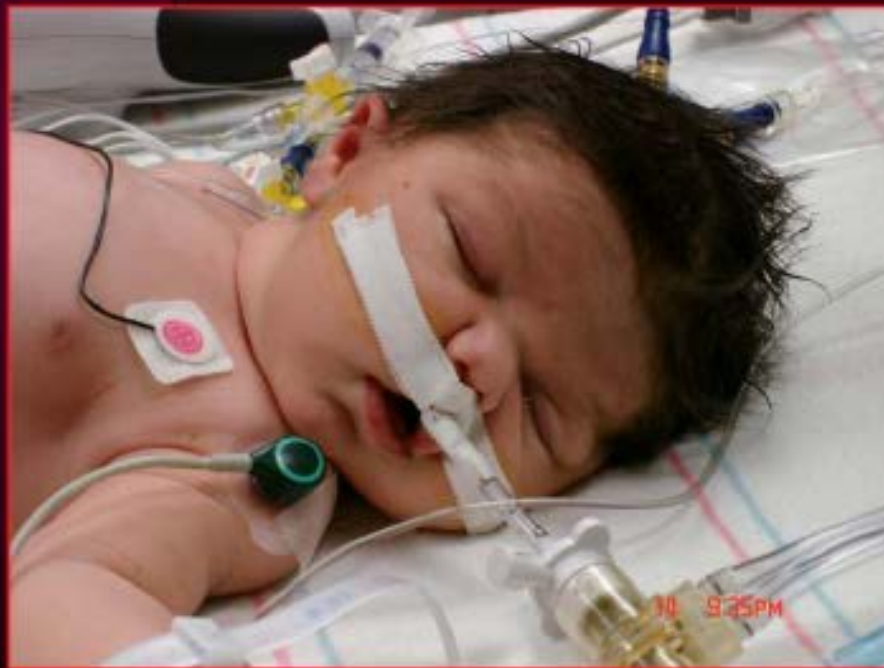

	CARDIOVASCULAR PROFILE SCORE: 10 POINTS=NORMAL		
	NORMAL	-1 POINT	-2 POINTS
Hydrops	None (2 pts)	Asthes or Pleural effusion or Pericardial effusion	Skin edema
Venous Doppler (Umbilical vein) (Ductus venosus)	UV DV (2 pts)	UV DV	UV pulsations
Heart Size (Heart Area/Chest Area)	≤ 0.34 (2 pts)	0.15 - 0.50	> 0.50 < 0.20
Cardiac Function	Normal TV & MV RVLV S.F. > 0.28 Biphasic filling (2 pts)	Holostystolic TR or RVLV S.F. < 0.28	Holostystolic MR or TR dP/dt < 400 or Monophasic filling
Arterial Doppler (umbilical artery)	UA (2 pts)	UA (AEDV)	UA (REDV)



Formal Fetal Echocardiography What is Important?

It Depends....

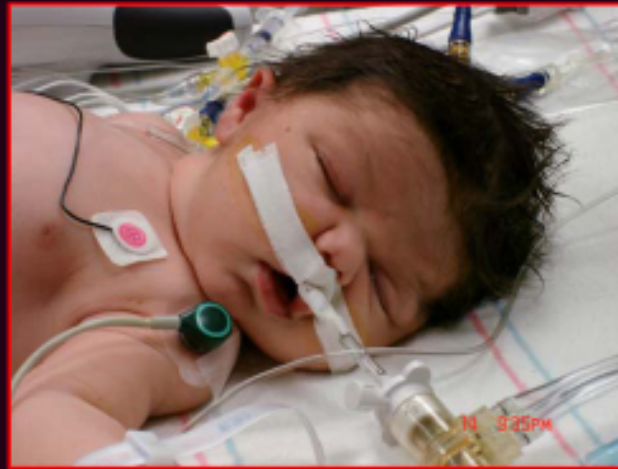

Clinical Importance



Academic Importance

Formal Fetal Echocardiography Clinical Importance



Determine Whether Normal/Abnormal
Diagnose Structural/Functional Cardiac Disease
Enable Assessment of Prognosis

Identify Candidates for Fetal Intervention

Identify Fetuses Who Will Need Urgent Neonatal Intervention

Enable Planning for Optimal Delivery: Time/Route/Location

Congenital Heart Disease

Risk Factors:

- **Family history of CHD**
- **Maternal pregestational diabetes**
- **Maternal collagen vascular disease**
- **Fetal arrhythmia**
- **Medications or teratogen exposure**
- **Fetus with extracardiac anomalies**
- **Fetus with chromosomal anomalies**
- **Suspected cardiac abnormality on US**

Screening Limitations In CHD

- Size & complexity of heart**
- US modality; Operator dependent**
- Lack of standardization & reproducibility of images**
- Gap between technology & skills**

ASE: Examples of Indications

Maternal

- Family history of CHD
- Metabolic disorders (eg, diabetes, PKU)
- Exposure to teratogens
- Exposure to ASA, ibuprofen, indocin
- Rubella infection
- Autoimmune disease (eg, SLE, Sjogren's)

- Familial inherited disorders
- In vitro fertilization

Fetal

- Abnormal obstetrical ultrasound
- Extracardiac abnormality
- Chromosomal abnormality
- Arrhythmia
- Hydrops
- Increased first trimester nuchal Translucency
- Multiple gestation/TTTS

ASE: Essential Components of the Fetal Echocardiogram

- **Anatomic overview**
 - Fetal number and position in the uterus
 - Establish stomach position and abdominal situs
 - Establish cardiac position
- **Biometric examination**
 - Cardiothoracic ratio
 - Biparietal diameter
 - Femur length

ASE: Essential Components of the Fetal Echocardiogram

- **Cardiac imaging (views/sweeps)**
 - Four-chamber view
 - Four-chamber view angled towards great arteries
 - (“Five-chamber” view)
 - Long-axis view (left ventricular outflow)
 - Long-axis view (right ventricular outflow)
 - Short-axis sweep (cephalad angling includes “3-vessel” view)
 - Caval long-axis view
 - Ductal arch view
 - Aortic arch view

ASE: Essential Components of the Fetal Echocardiogram

- **Doppler examination**
 - Inferior and superior vena cava
 - Pulmonary veins
 - Hepatic veins
 - Ductus venosus
 - Foramen ovale
 - Atrioventricular valves
 - Semilunar valves
 - Ductus arteriosus
 - Transverse aortic arch
 - Umbilical artery
 - Umbilical vein

ASE: Essential Components of the Fetal Echocardiogram

- **Measurement data**
 - Atrioventricular valve diameter
 - Semilunar valve diameter
 - Main pulmonary artery
 - Ascending aorta
 - Branch pulmonary arteries
 - Transverse aortic arch
 - Ventricular length
 - Ventricular short-axis dimensions
- **Examination of rhythm and rate**
 - M-mode of atrial and ventricular wall motion
 - Doppler examination of atrial and ventricular flow patterns

International Society of Ultrasound in Obstetrics/Gynecology

ISUOG consensus statement:
what constitutes a fetal echocardiogram?

W. LEE, L. ALLAN, J. S. CARVALHO, R. CHAOUI, J. COPEL, G.
DEVORE, K. HECHER, H. MUNOZ, T. NELSON, D. PALADINI
and S. YAGEL for the ISUOG Fetal Echocardiography Task Force

Ultrasound Obstet Gynecol 2008; 32: 239–242

ISUOG: Common Indications

Maternal

- First-degree relative of proband (mother or father) with CHD
 - Prior child with CHD born to mother and/or father
 - Pre-existing metabolic disease (DM, PKU)
 - Infections (Parvovirus B19, Rubella, Coxsackie)
- Autoimmune antibodies--Anti-Ro (SSA), Anti-La (SSB)
- Teratogen exposure (Retinoids, anticonvulsants, lithium)

Fetal

- Abnormal fetal cardiac screening exam
 - Fetal cardiac dysrhythmias
- Persistent bradycardia or tachycardia
 - Major extracardiac abnormality
 - Abnormal fetal karyotype
- Increased nuchal translucency thickness
 - Abnormal ductus venosus waveform
 - Hydrops

ISUOG: Systematic Evaluation

- cardiac axis and situs
- ventricular morphology
- pericardial effusions
- venous-atrial, atrioventricular and ventriculoarterial connections of the heart
- size and relationships of the left and right ventricular outflow tracts
- ductal and aortic arches
- interventricular septum
- atrial septum, atrial chamber size, and foramen ovale
- atrioventricular and semilunar valves
- flow across each heart connection, as seen with Doppler flow mapping

ISUOG: General Recommendations

- Structure
 - Laterality, situs, cardiac connections, other anomalies Mandatory
- Biometry
 - Normal heart Optional
 - Abnormal heart Desirable depending on anomaly
- Cardiac rhythm (M-mode or spectral Doppler)
 - Normal rhythm on two-dimensional ultrasonography Optional
 - Abnormal rhythm on two-dimensional ultrasonography Mandatory
- Cardiac function (e.g. M-mode or Doppler)
 - Normal function on two-dimensional ultrasonography Optional
 - Abnormal function on two-dimensional ultrasonography Desirable depending on anomaly
- Color Doppler ultrasonography Mandatory
- Power Doppler ultrasonography Optional
- Spectral Doppler ultrasonography
 - Normal cardiac anatomy Optional
 - Abnormal cardiac anatomy Desirable depending on anomaly
- Continuous-wave Doppler ultrasonography Optional
- Tissue Doppler ultrasonography Optional
- Three- and four-dimensional ultrasonography Optional

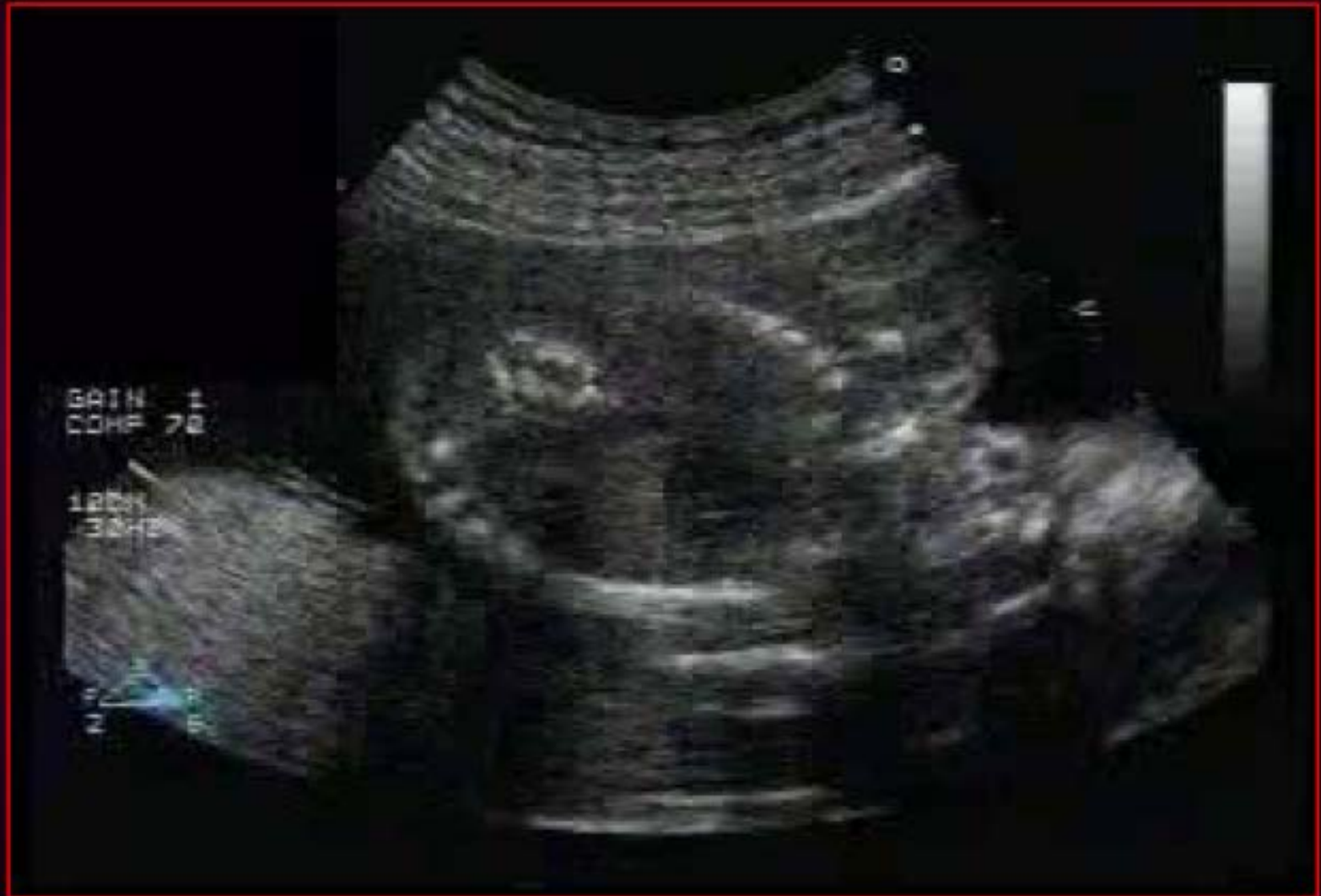Fetal Echocardiography

What's *Really* Important

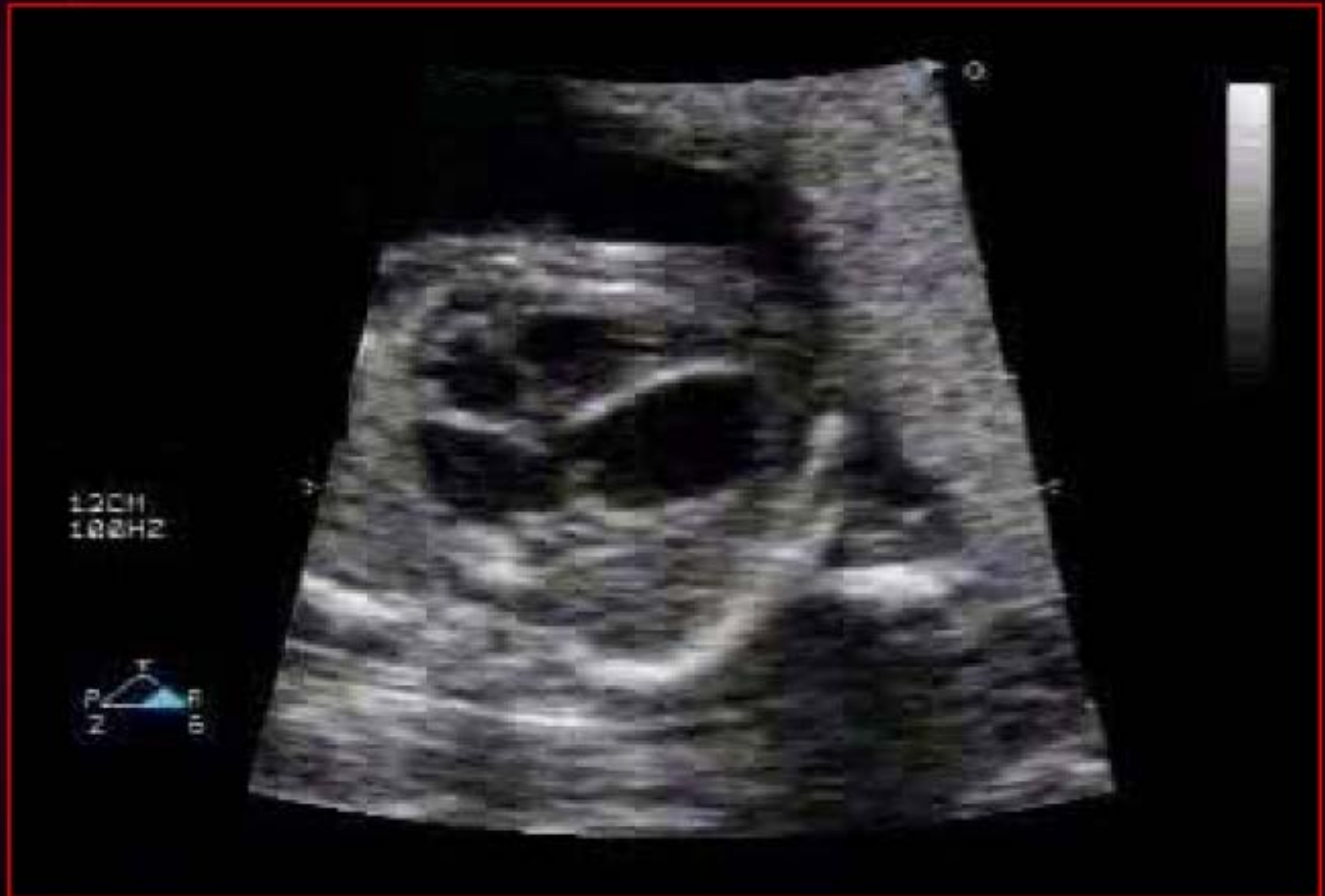

1. Optimize Fetal Lie/Image Quality
2. Read Out From Clips—Not Just Still Frame Images
3. Evaluate the Ventricular Septum Perpendicular to the Ventricular Septum
4. Evaluate Visceroatrial Situs, Four-Chamber and Outflow Tract Views
5. Detailed Evaluation of Valvar Morphology
6. Comprehensive Color Doppler Evaluation
7. Spectral Doppler, quantitative analyses *when clinically/academically indicated*

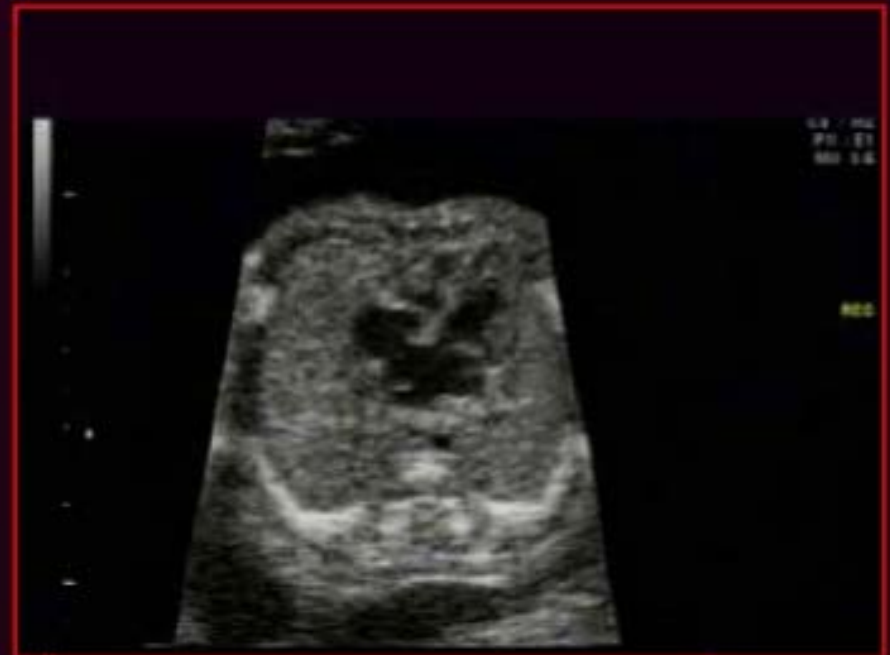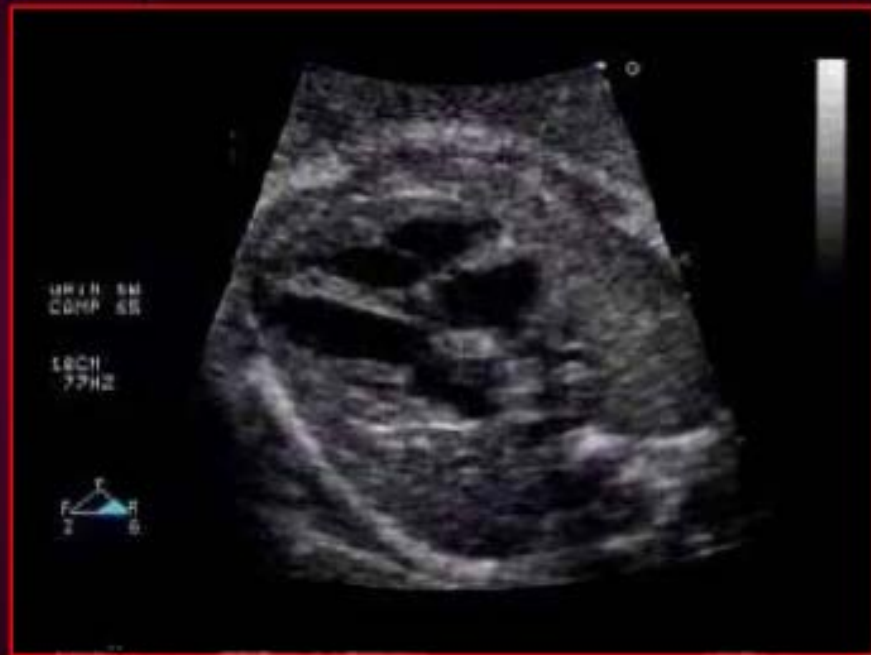Importance of Fetal Lie/Image Quality



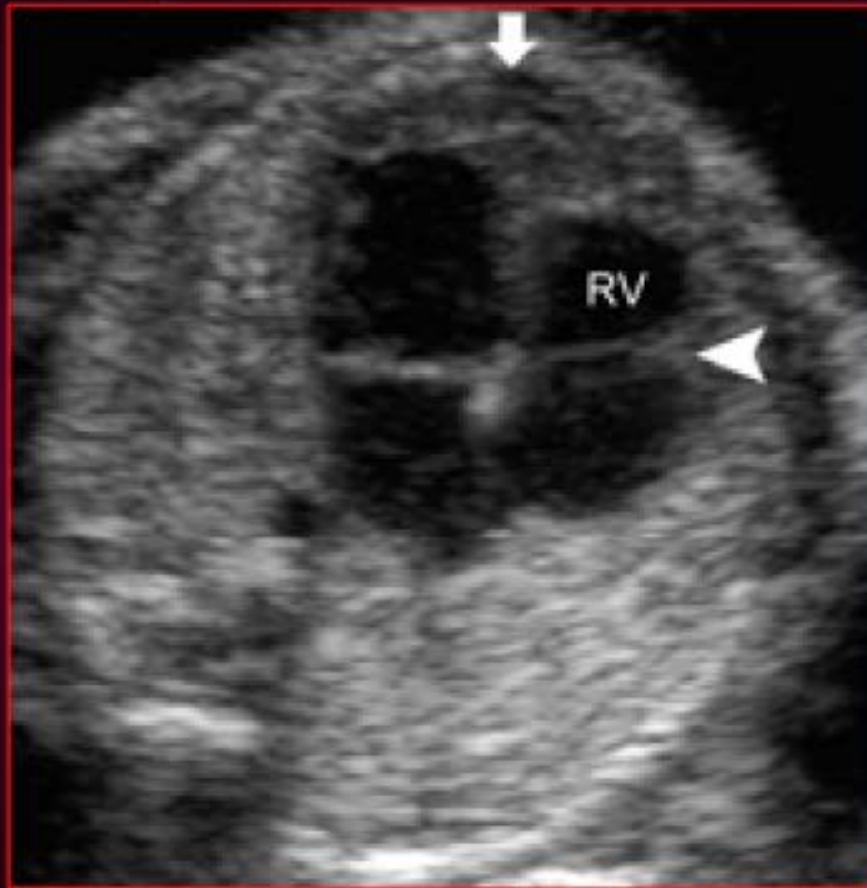
Importance of Clips: Function



Importance of Clips: Anatomy

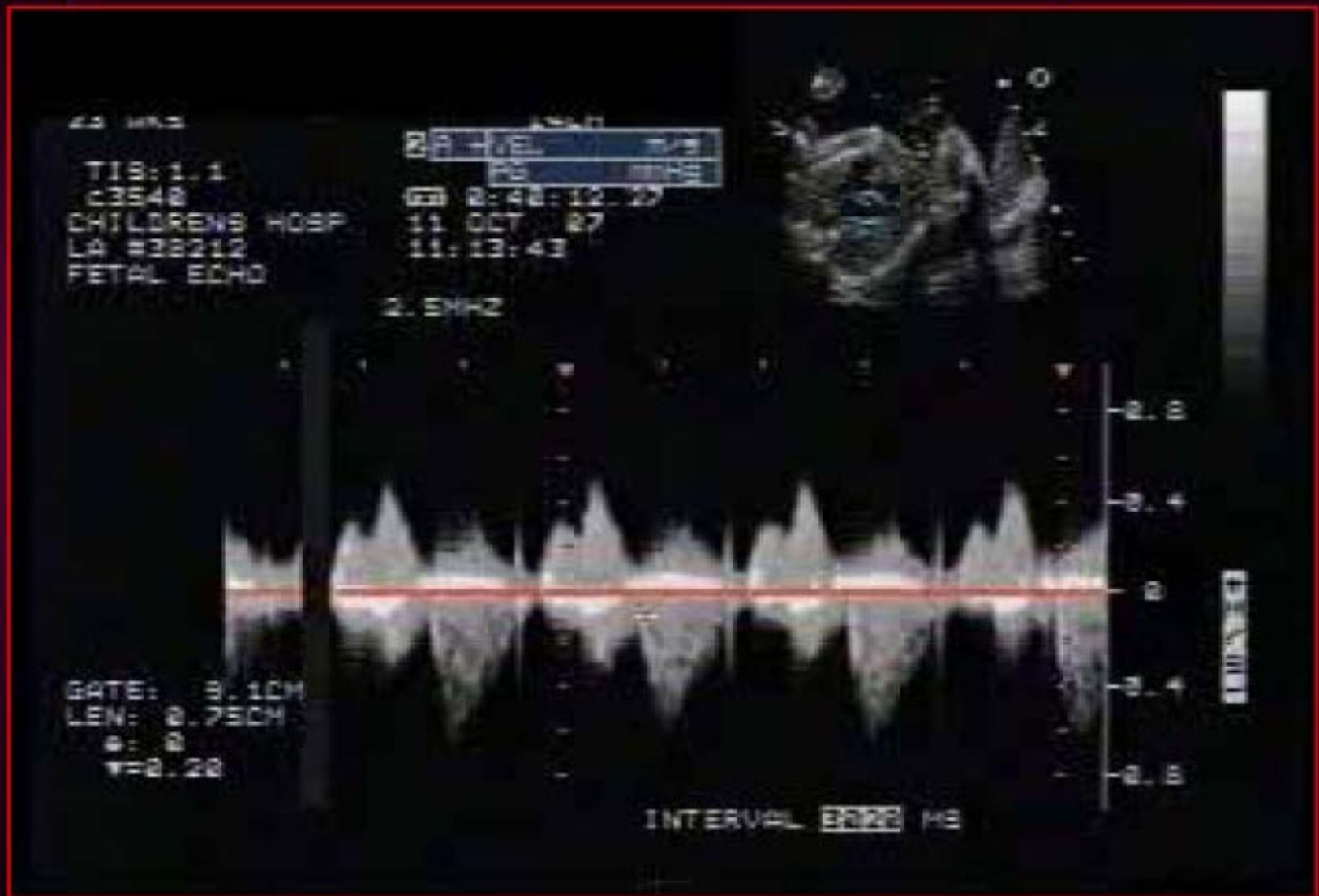


Importance of Clips: Anatomy



25 Week Fetus
G Melendres et al. JUM 2004

Doppler Evaluation of Fetal Rhythm/PR



Importance of Color



Detect subtle defects (VSD/TAPVR/PS)

Detect valvar regurgitation

Detect abnormal flow patterns

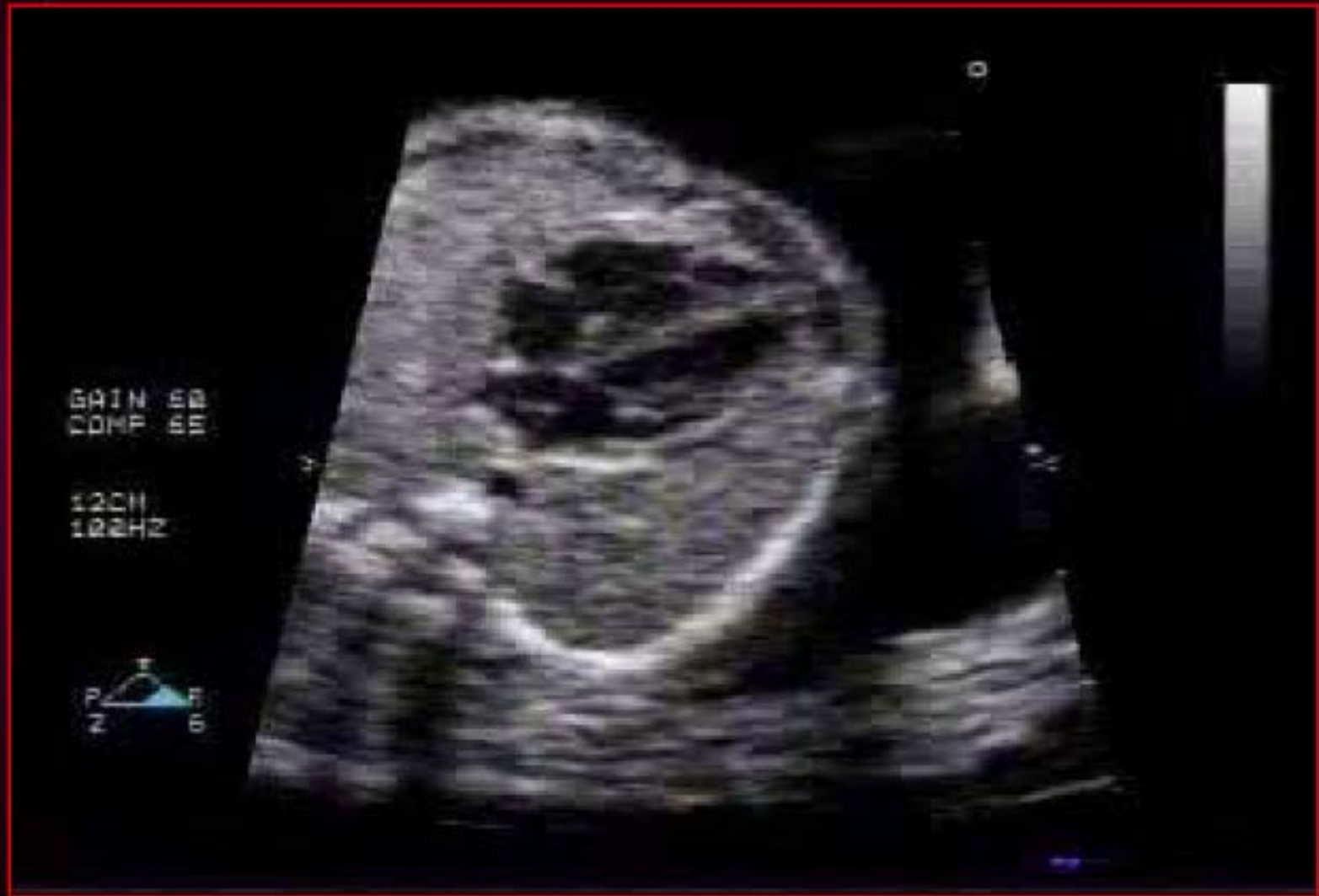Obstructed pulmonary veins

Reversed/Obstructed foramen ovale

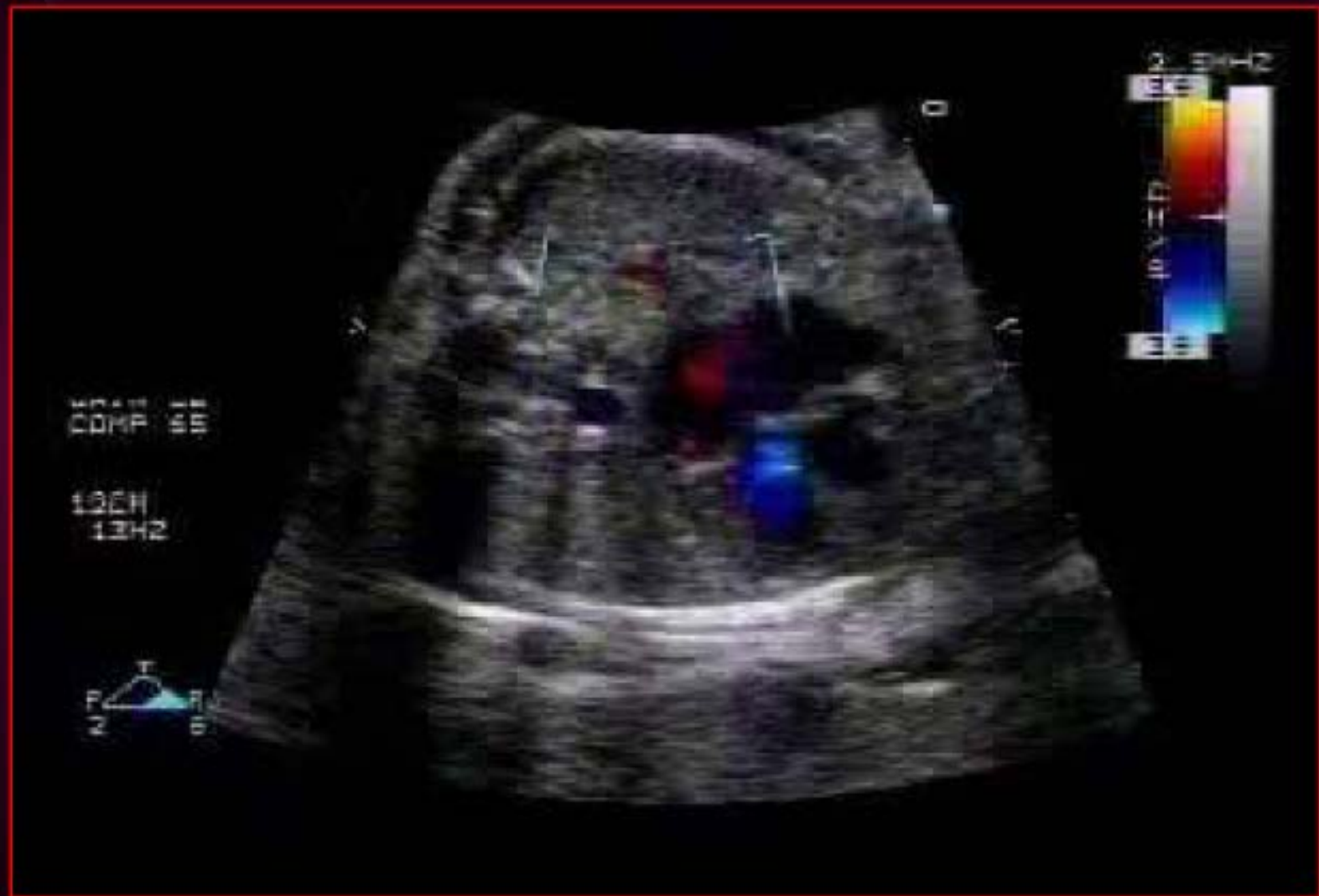Obstructed great arteries

Constricted/Reversed ductus arteriosus

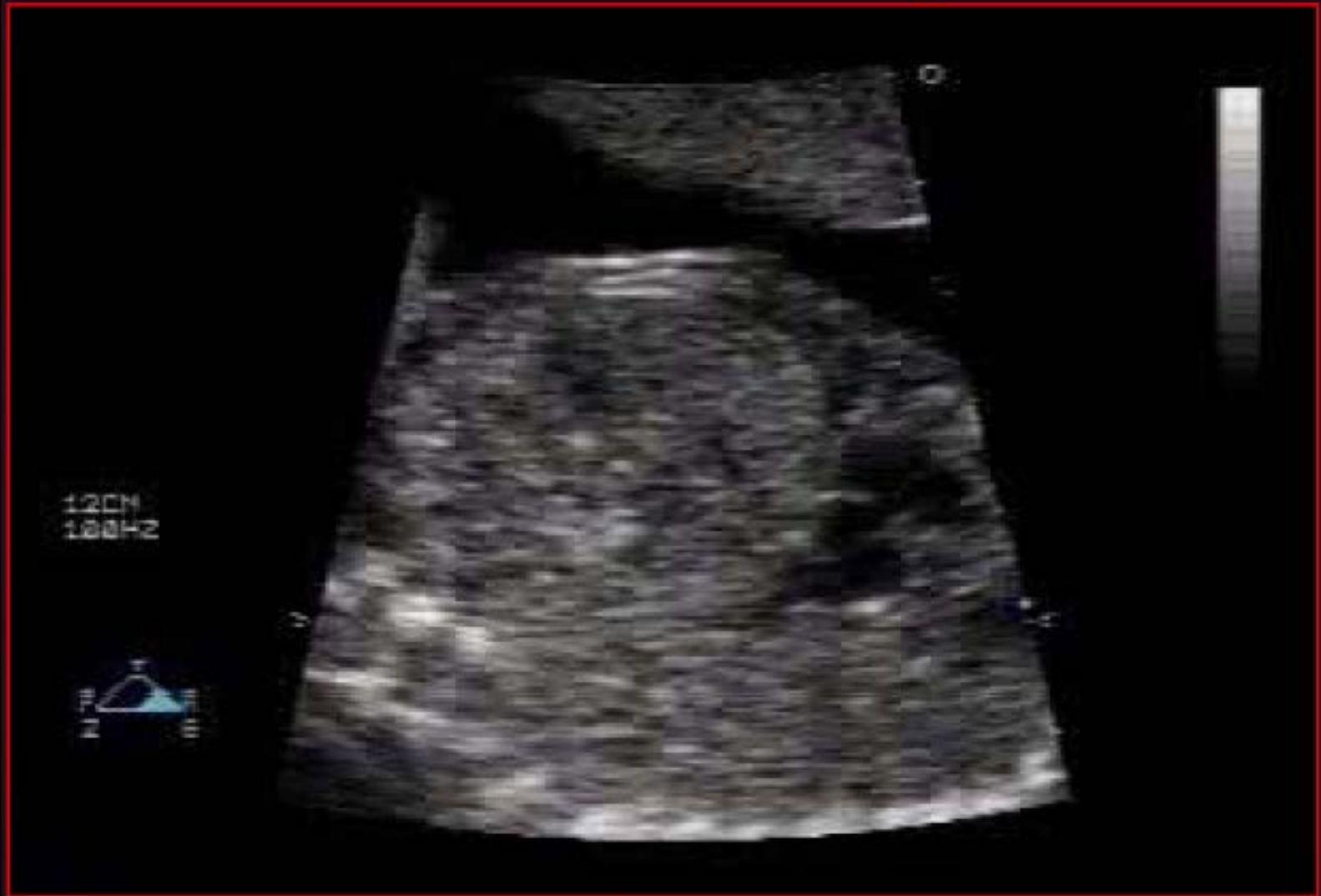Muscular Ventricular Septal Defect



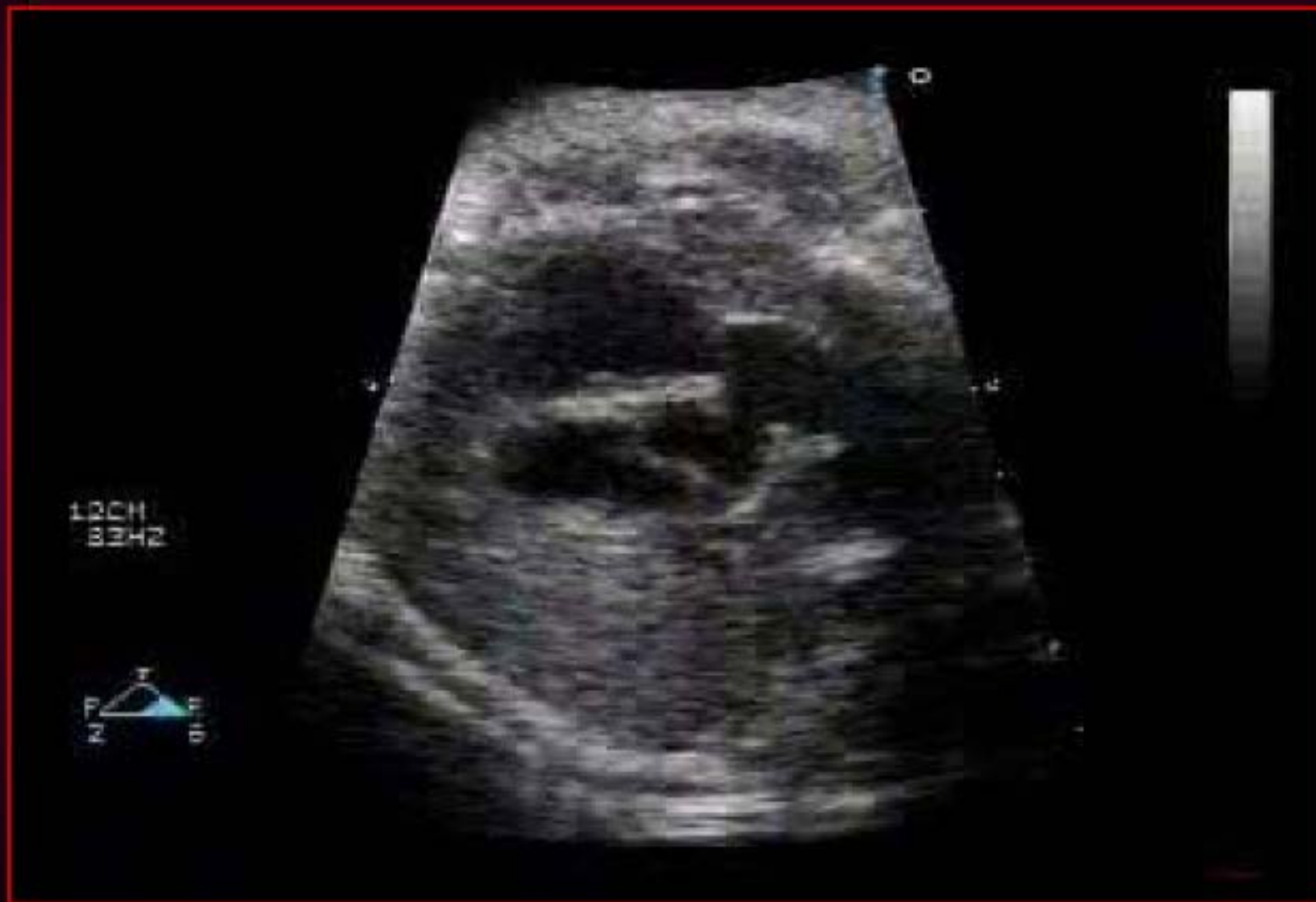Normal Pulmonary Veins



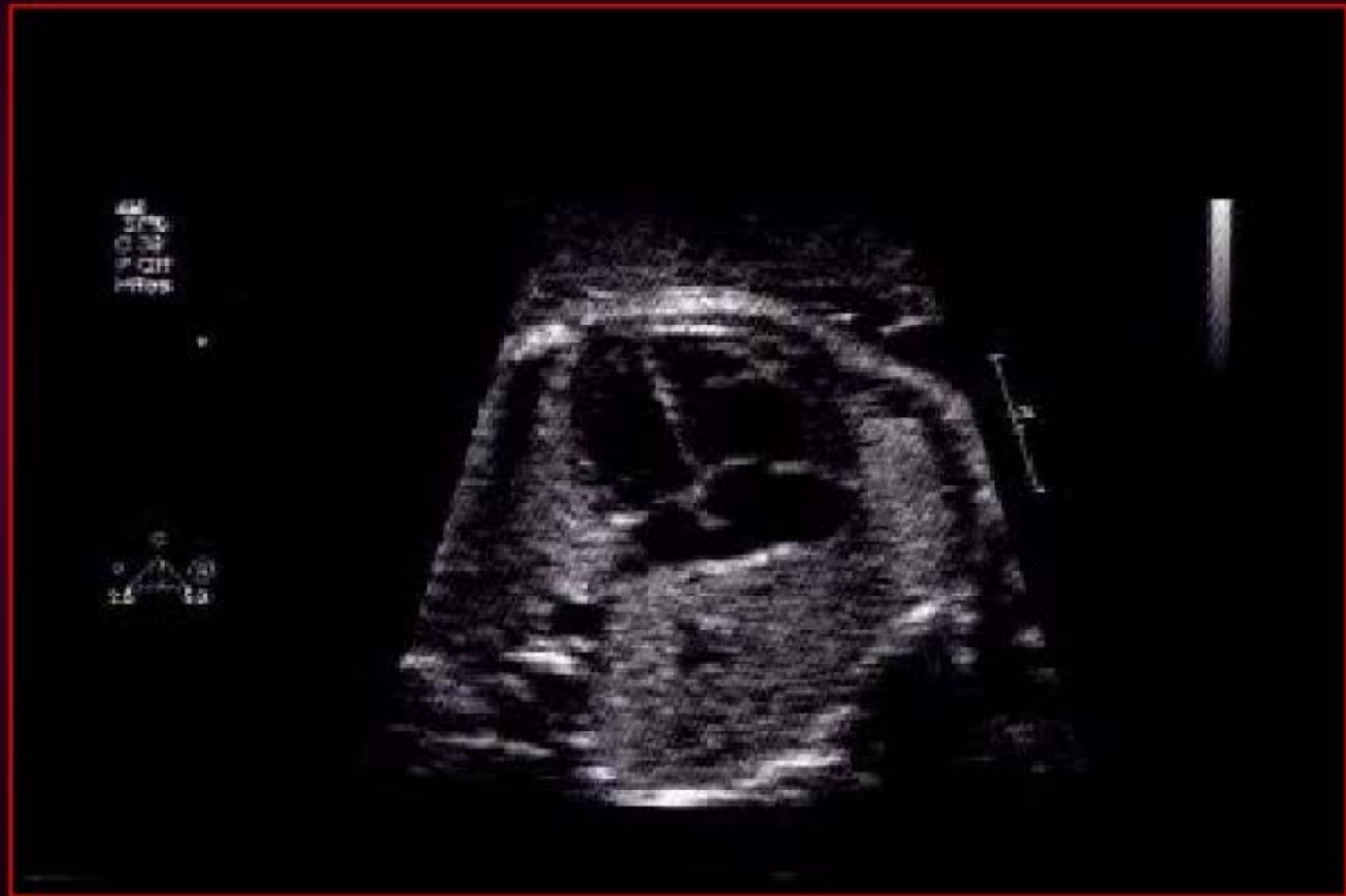Anomalous Pulmonary Veins



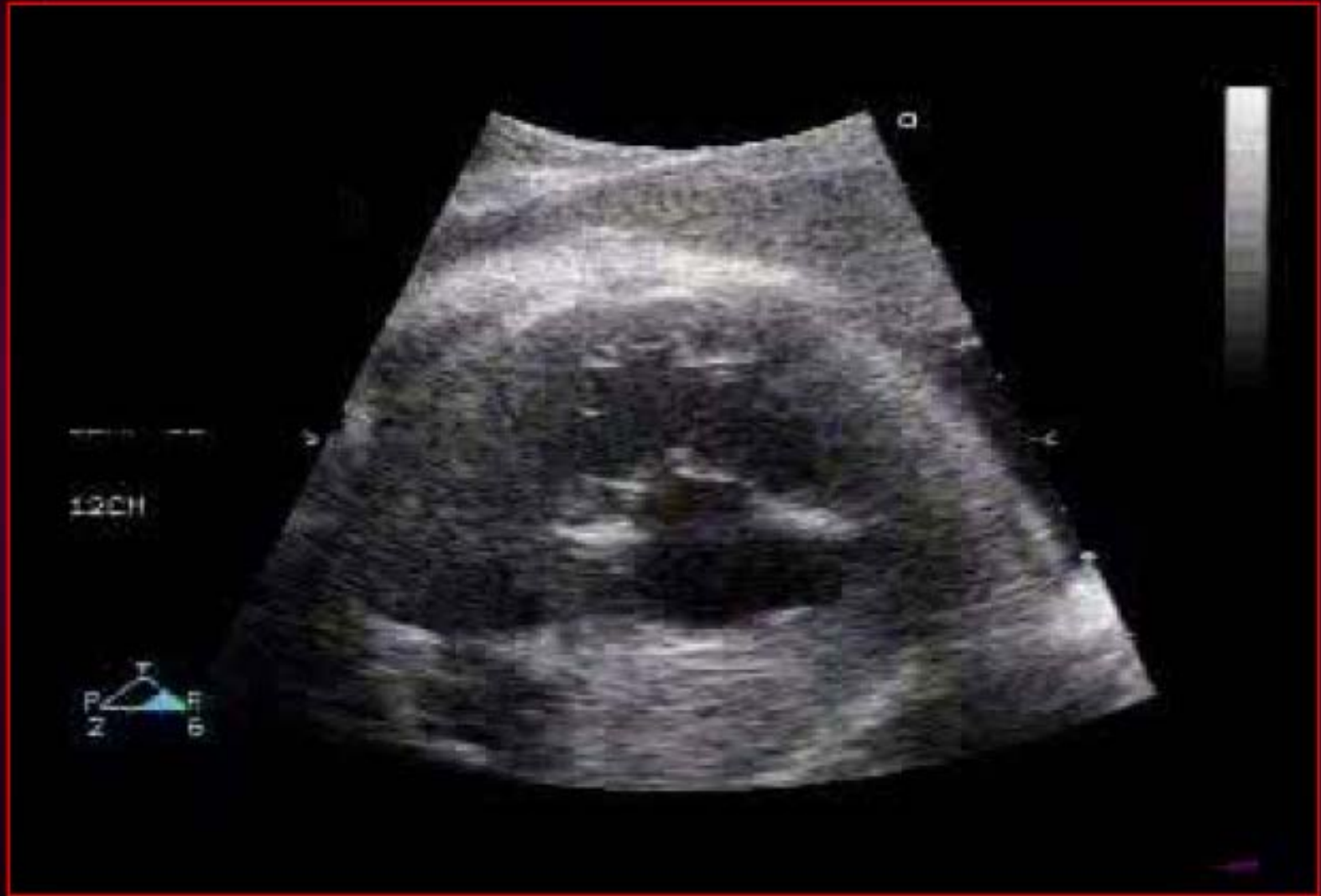Subtle Pulmonary Valve Abnormality



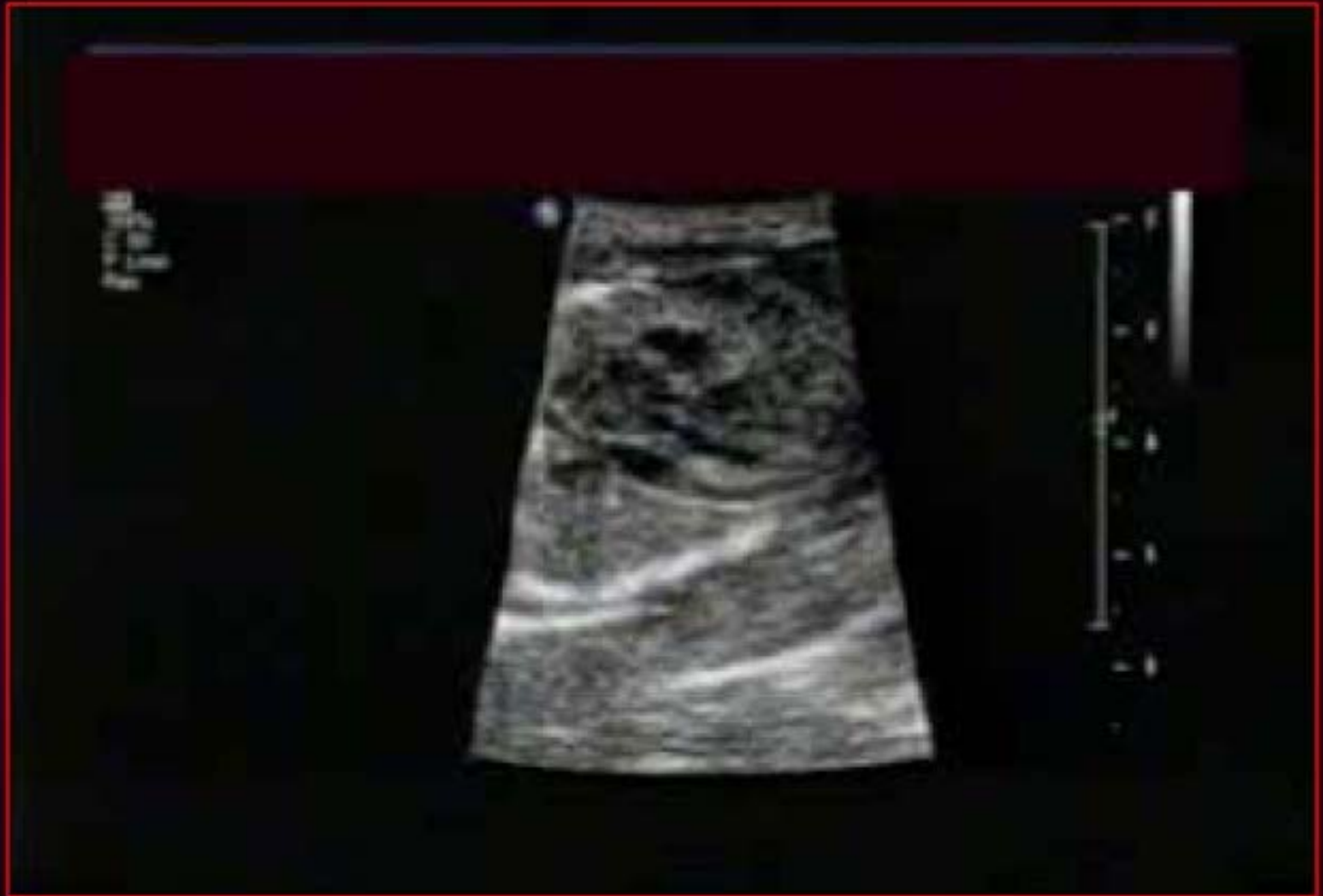Tricuspid Regurgitation



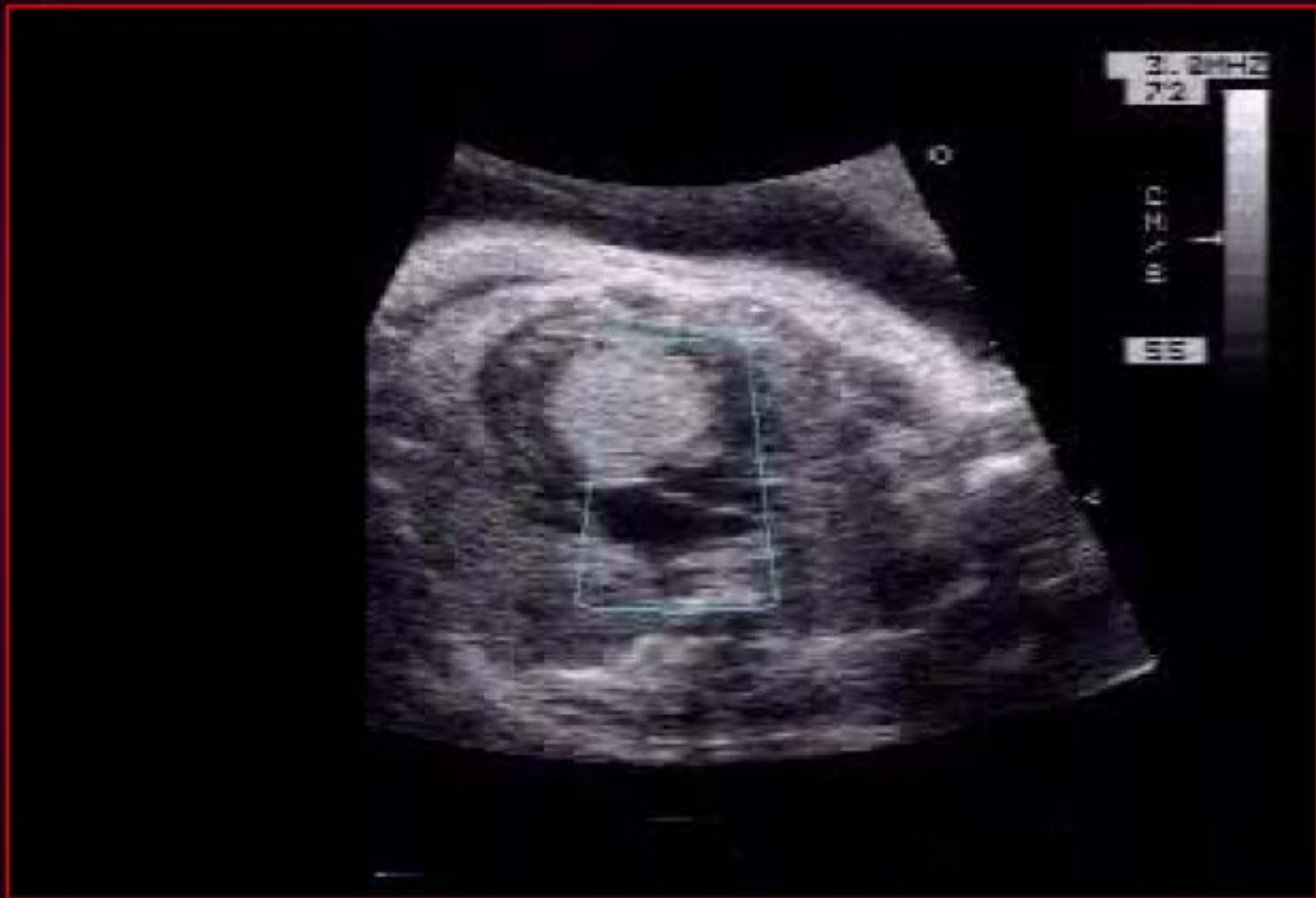AVC Regurgitation



Candidates for Fetal Intervention



Emergent Neonatal Intervention?



Potential Impact of Prenatal Diagnosis of CHD

PRICELESS



HLHS



Atrioventricular
Canal



TOF/Absent Pulm Valve



Tricuspid Atresia



TGA/VSD/PS