



www.who.org

Contents lists available at [SciVerse ScienceDirect](http://www.sciencedirect.com)

International Journal of Gynecology and Obstetrics

journal homepage: www.elsevier.com/locate/ijgo

FIGO CANCER REPORT 2012

Cancer of the vulva

Neville F. Hacker^a, Patricia J. Eifel^b, Jacobus van der Velden^c^a Gynecologic Oncology Cancer Centre, Royal Hospital for Women, Randwick, Australia^b Department of Radiation Oncology, M.D. Anderson Cancer Center, Houston, TX, USA^c Department of Gynecology, Academic Medical Center, Amsterdam, The Netherlands**1. Staging****1.1. Anatomy****1.1.1. Primary site**

Cases should be classified as carcinoma of the vulva when the primary site of growth is in the vulva. Tumors present in the vulva as secondary growths, from either a genital or extragenital site, will have to be excluded. Malignant melanoma should be separately reported. Any lesion that involves both the vagina and vulva (i.e. crosses the hymenal ring) should be classified as a carcinoma of the vulva. There must be histologic confirmation of the cancer.

1.1.2. Nodal stations

The inguinal and femoral nodes are the sites of regional spread.

1.1.3. Metastatic sites

Involvement of pelvic lymph nodes (external, hypogastric, obturator, and common iliac) is considered distant metastasis.

1.2. Surgical staging classification

The staging system for vulvar cancer has been based on surgical findings since 1988. The final diagnosis is dependent upon thorough histopathologic evaluation of the operative specimen (vulva and lymph nodes). Various modifications have been made over time, with a subdivision of Stage I added in 1994. The FIGO staging of vulvar cancer was last changed in 2009 by the FIGO Committee on Gynecologic Oncology [1], to give better prognostic discrimination between stages (Table 1).

1.2.1. Histopathologic types

Squamous cell carcinoma is the most frequent form of cancer of the vulva, and many cases, particularly in younger women, are HPV related. Malignant melanoma is the second most common tumor and should be reported separately. The histopathologic types are:

- Squamous cell carcinoma.
- Verrucous carcinoma.
- Paget's disease of vulva.
- Adenocarcinoma, not otherwise specified (NOS).
- Basal cell carcinoma, NOS.
- Bartholin's gland carcinoma.

1.2.2. Histopathologic grades (G)

- GX: Grade cannot be assessed.
- G1: Well differentiated.
- G2: Moderately differentiated.
- G3: Poorly or undifferentiated.

Table 1

Cancer of the vulva.

FIGO Stage	Description
I	Tumor confined to the vulva
IA	Lesions ≤ 2 cm in size, confined to the vulva or perineum and with stromal invasion ≤ 1.0 mm ^a , no nodal metastasis
IB	Lesions > 2 cm in size or with stromal invasion > 1.0 mm ^a , confined to the vulva or perineum, with negative nodes
II	Tumor of any size with extension to adjacent perineal structures (lower third of urethra, lower third of vagina, anus) with negative nodes
III	Tumor of any size with or without extension to adjacent perineal structures (lower third of urethra, lower third of vagina, anus) with positive inguinofemoral nodes
IIIA	(i) With 1 lymph node metastasis (≥ 5 mm), or (ii) With 1–2 lymph node metastasis(es) (< 5 mm)
IIIB	(i) With 2 or more lymph node metastases (≥ 5 mm), or (ii) With 3 or more lymph node metastases (< 5 mm)
IIIC	With positive nodes with extracapsular spread
IV	Tumor invades other regional (upper 2/3 urethra, upper 2/3 vagina), or distant structures
IVA	Tumor invades any of the following: (i) upper urethral and/or vaginal mucosa, bladder mucosa, rectal mucosa, or fixed to pelvic bone, or (ii) fixed or ulcerated inguinofemoral lymph nodes
IVB	Any distant metastasis including pelvic lymph nodes

^a The depth of invasion is defined as the measurement of the tumor from the epithelial–stromal junction of the adjacent most superficial dermal papilla to the deepest point of invasion.

2. Introduction

Carcinoma of the vulva is an uncommon tumor, representing about 4% of gynecologic malignancies. Because of the relatively small experience of individual institutions, randomized trials of therapeutic approaches are uncommon, and most studies are based on retrospective clinicopathologic reviews [2].

It is predominantly a disease of postmenopausal women, with the age-specific incidence increasing with increasing age. The external location of the vulva should prompt early presentation, but significant delays in diagnosis have been common with this cancer.

Ninety percent of cancers are squamous in origin, while melanomas, adenocarcinomas, basal cell carcinomas, verrucous

carcinomas, sarcomas, and other rare malignancies also occur. Most squamous carcinomas occur on the labia majora, but the labia minora, clitoris, and perineum may also be primary sites.

Vulvar intraepithelial neoplasia (VIN), a precursor lesion in some cases, tends to occur in younger women and may be associated with similar lesions of the cervix and vagina. A new classification of squamous VIN was introduced by the International Society for the Study of Vulvovaginal Disease (ISSVD) in 2004 [3]. The term VIN 1 is no longer used, and VIN 2 and 3 are simply called VIN. There are two types of VIN: (1) VIN, usual type (wartlike, basaloid, and mixed), which is HPV-related in most cases; and (2) VIN, differentiated type, which is seen particularly in older women, and is often associated with lichen sclerosus and/or squamous hyperplasia. VIN is best treated by superficial excision, with or without laser therapy [4,5].

Treatment of vulvar cancer used to be primarily surgical, but radiation therapy and, to a lesser extent, chemotherapy have been progressively integrated into the treatment protocol over the past 20 years. Therefore, management has evolved into an individualized multidisciplinary approach, and patients should be referred centrally to a gynecological cancer center where all relevant expertise is available [6,7]. **Level of Evidence B**

3. Screening

There is no screening procedure for vulvar cancer. However patients with a past history of cervical or vaginal cancer should have inspection of the vulva, with or without colposcopic examination, as part of their regular follow-up [8]. Patients with lichen sclerosus or a past history of VIN should also be kept under regular surveillance.

4. Squamous cell carcinoma

4.1. Presenting symptoms

Vulvar cancer may be asymptomatic, but most patients present with a vulvar lump or ulcer, which may or may not be painful. There is often a long-standing history of pruritus, which may be due to associated vulvar dystrophy. Bleeding or discharge is an occasional presenting symptom, and patients with advanced disease may present with a lump in the groin caused by metastases to groin lymph nodes.

4.2. Diagnosis

Diagnosis should be confirmed by biopsy prior to definitive treatment. A wedge or Keyes biopsy under local anesthesia in the office is usually sufficient. The biopsy should include some underlying stroma.

It is preferable not to excise the entire lesion because this makes it more difficult to plan the definitive excision.

If the lesion is 2 cm or less in diameter and depth of stromal invasion is <1 mm on wedge biopsy, complete excision of the lesion must be undertaken to allow serial sectioning to properly assess the depth of invasion.

4.3. Investigations

1. Pap smear of the cervix if the cervix is still in situ.
2. Colposcopy of the cervix and vagina because of the common association with other squamous intraepithelial lesions.
3. A CT scan of the pelvis and groins is often helpful to detect any enlarged lymph nodes in the groins or pelvis and erosion into underlying bony structures.
4. Routine full blood count, biochemical profile, and chest X-ray preoperatively.

4.4. Clinical practice guidelines

The clinical findings should be recorded on a staging diagram (e.g. Fig. 1). The findings according to the staging delineated in Tables 1 and 2 are usually listed on the reverse side of the diagram.

VULVA STAGING DIAGRAM

UNIT _____

CHART NO. _____

SURNAME _____ GIVEN NAME _____

D.O.B. _____ HEALTH CARE PLAN NO. _____

SITE: _____

HISTOLOGY: _____

New Recurrence Follow-up

Fig. 1. Vulvar staging diagram.

Table 2

Cancer of the vulva: FIGO staging compared with TNM classification.

FIGO Stage	Union for International Cancer Control (UICC)		
	T (tumor)	N (lymph nodes)	M (metastasis)
I	T1	N0	M0
IA	T1a	N0	M0
IB	T1b	N0	M0
II	T2/T3	N0	M0
IIIA	T1, T2, T3	N1a, N1b	M0
IIIB	T1, T2, T3	N2a, N2b	M0
IIIC	T1, T2, T3	N2c	M0
IVA	T4	N0–N2	M0
IVB	Any T	N3	M0

4.5. Treatment

4.5.1. Treatment of vulvar intraepithelial neoplasia

Various treatment modalities are available for treating intraepithelial lesions of the vulva [4,5]. Initial assessment should consist of multiple biopsies to ensure that the lesion is entirely intraepithelial. Patients with multifocal lesions should have biopsies

taken from several lesions. Once the diagnosis has been established, superficial local excision of the vulvar epithelium with a 0.5–1.0 cm margin is considered adequate for lesions of the lateral aspect of the vulva. Lesions involving the labia minora may also be treated by local excision but may respond favorably to laser vaporization. Laser treatment of the hair-bearing skin of the vulvar epithelium will usually produce depigmentation and destruction of hair follicles with subsequent loss of hair growth. Laser is also appropriate for clitoral lesions. Large lesions may be treated with a skinning vulvectomy and split-thickness skin graft. **Level of Evidence C**

Two randomized controlled trials have shown promising results with the topical immune response modifier, imiquimod, with complete response rates of 35%–81% reported [9,10]. Long-term follow-up of patients in one of the studies showed good long-term benefit [9]. **Level of Evidence A**

4.5.2. Invasive vulvar cancer

Management of vulvar cancer must be individualized. There is no standard operation and the emphasis is on performing the most conservative treatment consistent with cure of the disease [2].

In considering surgical treatment options, it is necessary to consider independently the most appropriate management of:

1. The primary lesion.
2. The groin lymph nodes.

In cases of locally advanced disease, treatment options for each site should be considered independently and then in the context of the overall management of the patient, in order to select a treatment that will optimize the likelihood of cure and minimize treatment-related morbidity.

4.5.3. Microinvasive vulvar cancer (Stage IA)

Stage IA carcinoma of the vulva is defined as a single lesion measuring 2 cm or less in diameter with a depth of invasion of 1.0 mm or less, the depth being measured from the epithelial–stromal junction of the most adjacent superficial dermal papilla to the deepest point of invasion. Lesions of this extent should be managed with wide local excision. If the local resection reveals features that are unfavorable (neural or vascular invasion), consideration should be given to more radical excision. Groin dissection is not necessary for lesions of this type [11,12]. **Level of Evidence C**

4.5.4. Early vulvar cancer

Tumors confined to the vulva without clinically suspicious lymph nodes may be considered early.

4.5.4.1. Management of the primary lesion (Fig. 2)

To decrease psychosexual morbidity, a more conservative operation than radical vulvectomy usually is indicated. The procedure may be called a radical wide local excision, and for localized lesions, this operation is as effective as radical vulvectomy in preventing local recurrence [2,13–17].

Surgical removal should achieve lateral margins of at least 1 cm, and the deep margin should be the inferior fascia of the urogenital diaphragm, which is co-planar with the fascia lata and the fascia over the pubic symphysis [13,16–18].

If the lesion is close to the urethra, the distal 1 cm of the urethra may be resected without jeopardizing urinary continence.

If there is associated VIN, this should be superficially excised to control symptoms, to exclude other areas of superficial invasion, and to prevent subsequent progression to invasive cancer. **Level of Evidence C**

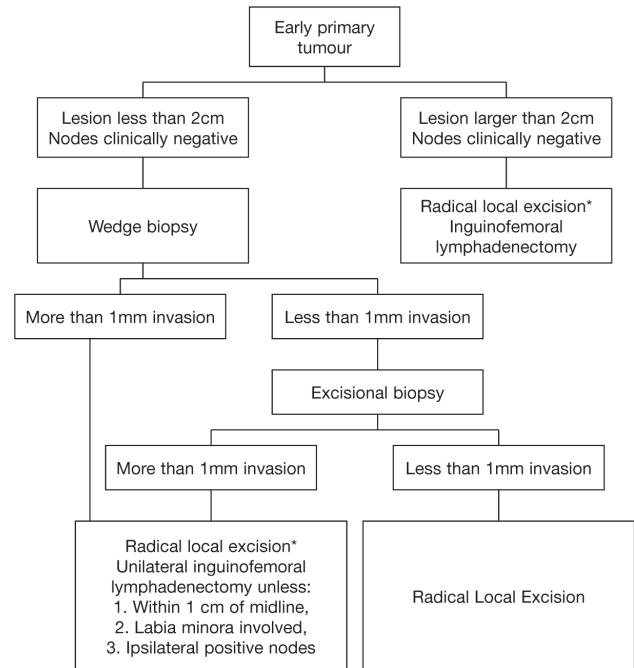


Fig. 2. Management of early vulvar cancer. *If there is associated VIN or lichen sclerosis, these areas may be superficially excised.

4.5.4.2. Management of groin lymph nodes

Recurrence in the groin carries a very high mortality, therefore appropriate groin treatment is the single most important factor in reducing mortality from early vulvar cancer [2].

All patients with FIGO stage 1B or stage II lesions or any tumor with more than 1-mm stromal invasion should have at least an ipsilateral inguinofemoral lymphadenectomy. **Level of Evidence C**

The incidence of positive contralateral nodes in patients with lateral FIGO stage 1B tumors is less than 1%, so unilateral groin dissection is appropriate for such lesions [2].

Bilateral groin dissection should be performed for midline tumors, and for those involving the anterior labia minora [19]. Large lateral tumors should probably also have bilateral dissection, and definitely if the ipsilateral nodes are positive [19].

Sentinel node excision is being increasingly practiced in some centers following the European multicenter observation study on sentinel node detection [20]. This procedure detects nodal metastasis in most patients with regional spread of disease and is associated with a lower rate of lymphedema than complete lymphadenectomy. Sentinel nodes were studied in a large prospective multicenter study (GROINSS-V) of 403 women with unifocal vulvar cancer Stage I and II, tumor size less than 4 cm, stromal invasion more than 1 mm, and clinically negative lymph nodes were included [20]. Lymphadenectomy was omitted in sentinel node negative women. Groin recurrences occurred in 2.3% with a median follow-up of 35 months. Overall disease-specific survival was 97% after 3 years and morbidity was substantially reduced. These results are equivalent to results of systematic inguinofemoral lymphadenectomy from an oncological point of view.

Owing to the small but definite false-negative rate with sentinel nodes, some patients, properly informed of the risks and benefits, will elect to have a full groin dissection, despite the greater complication rate [21,22]. **Level of Evidence B**

4.5.4.3. Groin dissection

It is recommended that both inguinal and femoral nodes be removed, as inguinal node dissection alone is associated with a higher incidence of groin recurrence [23]. **Level of Evidence A**

The femoral nodes are situated medial to the femoral vein within the fossa ovalis. There is no need to remove the fascia lata to dissect the femoral nodes [24]. Groin dissection may be safely performed through a triple incision approach, and this should improve primary healing [21,25]. **Level of Evidence C**

Alternatively, an en bloc approach may be used, particularly for clitoral or periclitoral lesions. To avoid skin necrosis, all subcutaneous tissue above the superficial fascia must be preserved.

Groin dissection (with postoperative radiation for patients with positive groin nodes) was found to be superior to groin irradiation in one small randomized trial [26]. Pretreatment imaging that might have detected grossly enlarged nodes was not performed in that early trial and the radiation technique used was considered inadequate to cover the at-risk inguino-femoral nodes [27]. Retrospective clinical reviews have suggested that radiation alone can control microscopic disease in the groins if adequate coverage of the inguino-femoral nodes is confirmed [28,29].

4.5.4.4. Management of patients with positive groin nodes

The Gynecologic Oncology Group demonstrated superior results for pelvic and inguinal radiation compared with pelvic node dissection for patients who had an inguinal lymph node dissection with findings of grossly positive or multiple positive groin nodes [30].

Level of Evidence A

Subsequent studies have further emphasized the prognostic significance of the morphology of positive groin nodes, particularly the size of the metastasis and the presence or absence of extracapsular spread [31–33].

Patients with 1 (and possibly 2) micrometastases (<5 mm) may not require adjuvant radiation therapy; several series suggest that their prognosis is good after surgery alone [32–34], but the number of patients in most series is too small to draw definitive conclusions.

Patients should receive bilateral pelvic and groin irradiation for the following indications:

- One macrometastasis (>5 mm diameter).
- Extracapsular spread.
- Two (possibly 3) or more micrometastases (<5 mm). **Level of Evidence B**

4.5.4.5. Radiation fields and doses

In most cases, fields should include the inguino-femoral nodes and at least the pelvic nodes distal to and including the bifurcation of the common iliac vessels. The upper border should be extended if there is extensive inguinal involvement or suspicion of pelvic node metastasis.

One of a variety of radiation techniques can be selected, depending on the patient's body habitus and extent of disease. Treatments should always be based on 3-dimensional planning using high-quality CT or MRI images.

Combined photon and electron techniques are often used to treat the regional nodes without overdosing the femoral heads. However, care must be taken to completely include both the superficial and deep inguinal lymph nodes. In thin patients, care must be taken to avoid underdosage of superficial inguinal nodes by high-energy photon beams. If electron beams are used, the energy must be sufficient to cover the femoral nodes. In recent years, some clinicians have begun to use intensity-modulated radiation therapy (IMRT) or other inverse-planned, computer-controlled delivery techniques to treat vulvar cancer. Although these techniques can reduce acute radiation effects in collateral skin and soft tissue, the treatment planning and delivery are complex and the opportunity for unanticipated underdosage of the target is substantial, suggesting that these cases may be best treated by clinicians who have considerable specialized expertise.

The dose of radiation is determined by the initial extent of regional disease and any known residual. After a groin dissection with microscopic inguinal metastases, 50 Gy in 1.8–2.0 Gy fractions is usually sufficient.

If there are multiple positive nodes or if there is evidence of extracapsular extension, somewhat higher doses up to 60 Gy may be given to a reduced volume. Gross residual disease may require doses of 60–70 Gy.

The effectiveness of concurrent chemotherapy in the treatment of groin and pelvic lymph nodes is unknown.

4.5.5. Advanced vulvar cancer

Patients with FIGO Stage III and IV primary tumors or bulky positive groin nodes are considered to have advanced vulvar cancer. For such patients, multimodality treatment planning is particularly important.

4.5.5.1. Management of groin lymph nodes

It is desirable to determine the status of the groin nodes prior to planning the overall treatment [1]. Pelvic CT or MRI should be part of the patient's initial workup. These studies are particularly helpful in suggesting the extent of pelvic or inguinal lymphadenopathy (Fig. 3). Pelvic MRI can also provide useful information about the anatomical extent of the primary lesion, but is not mandatory.

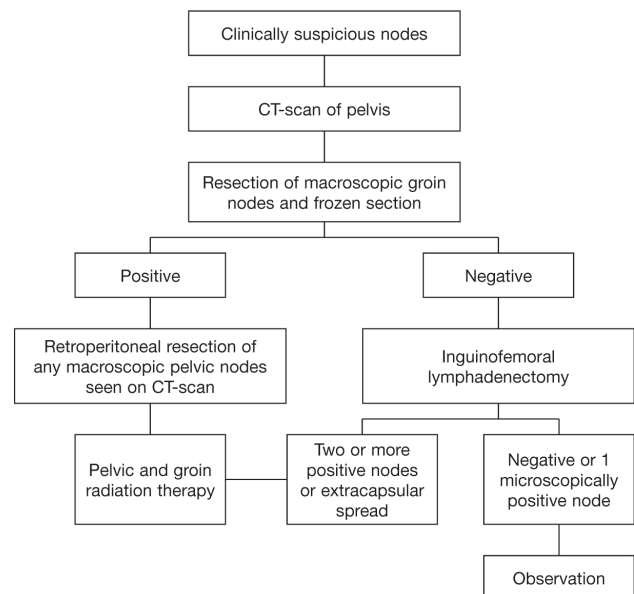


Fig. 3. Management of clinically suspicious groin nodes.

If there are no suspicious nodes in the groin on CT scan, bilateral inguino-femoral lymphadenectomy may be performed. If final histologic assessment reveals positive nodes, adjuvant radiation to the groin and pelvis should follow the guidelines given for early stage disease. If the nodes are negative, groin and pelvic radiation may be eliminated.

Alternatively, primary chemoradiation therapy may be used to treat the primary tumor as well as the groin and pelvic nodes if surgery is deemed inappropriate for the individual patient.

If nodes are clinically positive, a complete lymphadenectomy should be avoided because full groin dissection together with postoperative groin irradiation may result in severe lymphedema. Only enlarged nodes from the groin and pelvis should be removed if feasible, and the patient given postoperative groin and pelvic radiation [35]. **Level of Evidence C**

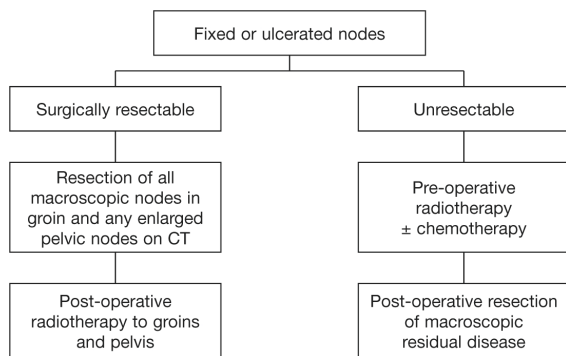


Fig. 4. Management of clinically obvious groin nodes.

If there are ulcerated or fixed groin nodes, they should be resected if not infiltrating muscle or femoral vessels, as determined by imaging studies. If irresectable, they should be biopsied to confirm the diagnosis then treated with primary radiation, with or without chemotherapy. If appropriate, the nodes may be resected following the radiation (Fig. 4) [36]. **Level of Evidence C**

4.5.5.2. Management of the primary tumor (Fig. 5)

This should usually follow dissection of the groins.

If it is possible to resect the primary lesion with clear surgical margins and without sphincter damage leading to urinary or fecal incontinence, primary surgical excision is desirable.

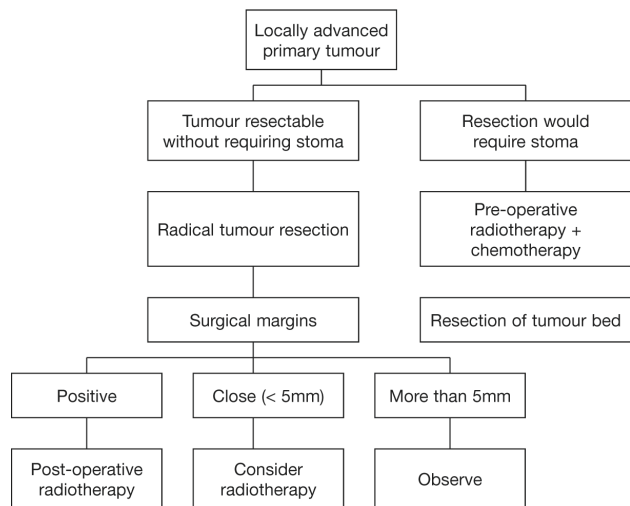


Fig. 5. Management of advanced primary tumor. Treatment should follow dissection of the groins. Groin and pelvic radiation should follow standard indications.

If primary surgery would result in the need for a bowel or urinary stoma, it is preferable to employ primary chemoradiation therapy, followed usually by a more limited resection of the tumor bed or any obvious residual disease [37,38].

Chemoradiation has been used extensively for large lesions that would damage central structures (anus, urethra) if surgically excised and complete response without the need for post-treatment surgery is well described [39–42].

The groin nodes and pelvis may need to be included in the treatment field depending on the status of the groin nodes, as determined initially.

Neoadjuvant cisplatin and 5-fluorouracil have also been reported to be effective for preservation of the anal sphincter and/or urethra in patients with advanced vulvar cancer involving these sites [43]. 5-fluorouracil and mitomycin C are frequently used concomitantly with radiation for treatment of advanced lesions.

4.5.5.3. Radiation protocol

If the groin nodes are positive and meet the requirements described earlier for adjuvant radiation, the initial radiation treatment fields should include the pelvis, inguinal nodes, and primary site, which are treated to a total dose of at least 50 Gy. Care must be taken to adequately cover the inguinal nodes.

Some clinicians prefer to treat in an open-leg position but care must be taken to apply bolus to the vulva to avoid underdosage of the skin.

Areas of gross disease or particularly high risk are usually boosted with appositional fields of electrons selected to provide an adequate dose to the surface and at depth. Gross vulvar disease probably requires 60–70 Gy to achieve local control, although investigators are currently exploring a wide variety of chemoradiation schedules, and the relationship between dose and local control remains somewhat uncertain. **Level of Evidence C**

4.5.5.4. Close surgical margins

Postoperative radiation may be used for close surgical margins (<5 mm), if the margins cannot be re-excised [44]. Although postoperative radiation therapy improves local control in high-risk patients, the impact on overall survival is less clear because most local recurrences are able to be salvaged with additional surgery or radiation [13].

In some cases, the positive margin may be boosted with brachytherapy, although this technique requires experience to avoid an excessive risk of necrosis. Alternatively, the operative bed may be treated with an appositional electron field or in some cases, carefully planned conformal external beam irradiation. **Level of Evidence C**

5. Special situation

5.1. Vulvar melanoma

Vulvar melanoma is the second most common neoplasm of the vulva. The majority of lesions involve the clitoris or labia minora. The Clark or Breslow modifications to the micro staging system should be used for the staging of vulvar melanoma rather than the more common TNM/FIGO system. These systems measure the depth of invasion in terms of the descriptive histology of the skin.

Any pigmented lesion on the vulva should be excised for diagnosis unless it has been known to be present and unchanged for some years.

In line with trends toward more conservative surgery for cutaneous melanomas, there is a trend toward more conservative resection of vulvar melanomas [45–47]. Primary lesions should be treated by radical local excision, with margins around the lesion of at least 1 cm. **Level of Evidence C**

The role of node dissection is also controversial, but the Intergroup Surgical Melanoma Program has conducted a prospective, multi-institutional randomized trial of elective node dissection versus observation for intermediate thickness cutaneous melanomas (1–4 mm) [48]. There were 740 patients entered into the trial, and elective node dissection resulted in a significantly better survival for patients 60 years of age or younger, patients with tumors 1–2 mm thick, and patients without tumor ulceration.

5.2. Bartholin's gland cancer

Cancers arising in the Bartholin's gland may be either transitional or squamous types, arising from the duct, or an adenocarcinoma from the gland itself. Adenoid cystic and adenosquamous variants have also been reported. Adenocarcinomas of the vulva occur, on average, approximately a decade earlier than invasive squamous cancers. Frequently, diagnosis is made after resection of what is thought to be a persisting Bartholin's cyst.

The standard approach for Bartholin's gland carcinomas has been radical vulvectomy and bilateral groin dissection. However, ipsilateral groin dissection and radical hemi-vulvectomy may be equally effective for early lesions [49]. Because these lesions are deep in the ischioanal fossa, surgical margins are more likely to be close, particularly for bulky lesions, and postoperative radiation to the vulva may decrease the likelihood of local recurrence [49].

Level of Evidence C

If the ipsilateral groin nodes are positive, bilateral groin and pelvic radiation may decrease regional recurrence.

For adenoid cystic lesions, radical local excision alone is the treatment of choice, with adjuvant local radiation recommended for positive margins or perineural invasion. **Level of Evidence C**

5.3. Paget's Disease

This is predominantly an intraepithelial lesion, but on occasion it may be associated with an underlying invasive adenocarcinoma. The disease occurs predominantly in the menopausal or postmenopausal population. Most patients will present with vulvar discomfort and itching and on examination, an eczematoid, weeping lesion is often seen. Diagnosis is usually confirmed by biopsy, which will generally differentiate an intraepithelial from an invasive lesion [2,50].

Intraepithelial Paget's disease requires superficial local excision. It is difficult to obtain clear margins with this disease, as often the underlying histologic change will extend far beyond the macroscopic lesion. More recently, there has been a move to perform less radical resection for intraepithelial lesions, with re-excision at a later date should lesions become symptomatic or clinically visible. Lesions that involve or extend into the urethra or anus can be particularly difficult to manage, and may require laser therapy.

If there is an underlying adenocarcinoma, the invasive component should be treated by radical local excision with margins of at least 1 cm. At least an ipsilateral inguinofemoral lymphadenectomy should be performed for unilateral lesions, with adjuvant radiation following the same indications as for squamous carcinomas. **Level of Evidence C**

6. Pathology

The surgical specimen should be correctly orientated and photographed. Photographs should be used to indicate the origin of tissue blocks. The size of the specimen should be measured and the dimensions of any visible tumor measured. The macroscopic tumor-free surgical margins should be measured. Sections are taken through the tumor to measure tumor depth. Sections should be taken from urethral, anal, and vaginal resection margins.

Lymph nodes should be carefully dissected out and the site from which they are removed recorded. A full cross-section of each lymph node should be embedded.

The following histological points should be noted:

- Tumor type: keratinizing; basaloid; Bowenoid.
- Depth of invasion: measured from the epithelial–stromal junction of the adjacent dermal papilla to the deepest point of invasion by the tumor.
- Tumor grade.
- Histological measurement of tumor-free margins and statement as to whether tumor is completely excised.
- Presence or absence of perineural or vascular space invasion.
- Nature of the adjacent nonmalignant squamous epithelium: VIN; lichen sclerosus; squamous hyperplasia; HPV-associated changes.
- Sites and number of nodes examined and number of positive nodes. Presence or absence of extracapsular extension.

Conflict of interest

The authors declare that they have no conflicts of interest.

References

- FIGO Committee on Gynecologic Oncology. Revised FIGO staging for carcinoma of the vulva, cervix, and endometrium. *Int J Gynecol Obstet* 2009;105(2):103–4.
- Hacker NF. Vulvar cancer. In: Berek JS, Hacker NF, eds. *Berek and Hacker's Gynecologic Oncology*. 5th ed. Philadelphia: Lippincott Williams & Wilkins; 2009, pp. 536–75.
- Sideri M, Jones RW, Wilkinson EJ, Preti M, Heller DS, Scurry J, et al. Squamous vulvar intraepithelial neoplasia: 2004 modified terminology. ISSVD Vulvar Oncology Subcommittee. *J Reprod Med* 2005;50(11):807–10.
- Jones R, Rowan DM. Vulvar intraepithelial neoplasia III: a clinical study of the outcome in 113 cases with relation to the later development of invasive vulvar carcinoma. *Obstet Gynecol* 1994;84(5):741–5.
- Herod JJ, Shafi MI, Rollason TP, Jordan JA, Leusley DM. Vulvar intraepithelial neoplasia: long term follow up of treated and untreated women. *Br J Obstet Gynaecol* 1996;103(5):446–52.
- van der Velden J, van Lindert AC, Gimbrere CH, Oosting H, Heintz AP. Epidemiologic data on vulvar cancer: comparison of hospital with population-based data. *Gynecol Oncol* 1996;62(3):379–83.
- Rhodes CA, Cummins C, Shafi M. The management of squamous cell vulvar cancer: a population based retrospective study of 411 cases. *Br J Obstet Gynaecol* 1998;105(2):200–5.
- Peters RK, Mack TM, Bernstein L. Parallels in the epidemiology of selected anogenital carcinomas. *J Natl Cancer Inst* 1984;72(3):609–15.
- Terlou A, van Seters M, Ewing PC, Aaronson NK, Gundy CM, Heijmans-Antonissen C, et al. Treatment of vulvar intraepithelial neoplasia with topical imiquimod: Seven years median follow-up of a randomized clinical trial. *Gynecol Oncol* 2011;121(1):157–62.
- Mathiesen O, Buus SK, Cramers M. Topical imiquimod can reverse vulvar intraepithelial neoplasia: a randomised, double-blinded study. *Gynecol Oncol* 2007;107(2):219–22.
- Iversen T, Abeler V, Aalders J. Individualized treatment of stage I carcinoma of the vulva. *Obstet Gynecol* 1981;57(1):85–90.
- Hacker NF, Berek JS, Lagasse LD, Nieberg RK, Leuchter RS. Individualization of treatment for stage I squamous cell vulvar carcinoma. *Obstet Gynecol* 1984;63(4):155–62.
- Tantipalakorn C, Robertson G, Marsden DE, Gebksi V, Hacker NF. Outcome and patterns of recurrence for International Federation of Gynecology and Obstetrics (FIGO) stages I and II squamous cell vulvar cancer. *Obstet Gynecol* 2009;113(4):895–901.
- Farias-Eisner R, Cirisano FD, Grouse D, Leuchter RS, Karlan BR, Lagasse LD, et al. Conservative and individualized surgery for early squamous carcinoma of the vulva: the treatment of choice for stage I and II (T1–2NO–1MO) disease. *Gynecol Oncol* 1994;53(1):55–8.
- Burke TW, Levenback C, Coleman RL, Morris M, Silva EG, Gershenson DM. Surgical therapy of T1 and T2 vulvar carcinoma: further experience with radical wide excision and selective inguinal lymphadenectomy. *Gynecol Oncol* 1995;57(2):215–20.
- Heaps JM, Fu YS, Montz FJ, Hacker NF, Berek JS. Surgical pathological variables predictive of local recurrence in squamous cell carcinoma of the vulva. *Gynecol Oncol* 1990;38(3):309–14.
- De Hullu JA, Hollema H, Lolkema S, Boezen M, Boonstra H, Burger MP, et al. Vulvar carcinoma: the price of less radical surgery. *Cancer* 2002;95(11):2331–8.
- Chan JK, Sugiyama V, Pham H, Gu M, Rutgers J, Osann K, et al. Margin distance and other clinico-pathological prognostic factors in vulvar carcinoma: a multivariate analysis. *Gynecol Oncol* 2007;104(3):636–41.
- Iversen T, Aas M. Lymph drainage from the vulva. *Gynecol Oncol* 1983;16(2):179–89.
- Van der Zee AG, Oonk MH, De Hullu JA, Ansink AC, Vergote I, Verheijen RH, et al. Sentinel node dissection is safe in the treatment of early stage vulvar cancer. *J Clin Oncol* 2008;26(6):884–9.
- de Hullu JA, Ansink AC, Tymstra T, van der Zee AG. What doctors and patients think about false-negative sentinel lymph nodes in vulvar cancer. *J Psychosom Obstet Gynaecol* 2001;22(4):199–203.
- Gan S, Magarey C, Schwartz P, Papadatos G, Graham P, Vallentine J. Women's choice between sentinel lymph node biopsy and axillary clearance. *Aust N Z J Surg* 2002;72(2):110–3.
- Stehman FB, Bundy BN, Dvoretzky PM, Creasman WT. Early stage I carcinoma of the vulva treated with ipsilateral superficial inguinal lymphadenectomy and modified radical hemivulvectomy: a prospective study of the Gynecologic Oncology Group. *Obstet Gynecol* 1992;79(4):490–7.
- Micheletti L, Borgno G, Barbero M, Preti M, Cavanna L, Nicolaci P, et al. Deep femoral lymphadenectomy with preservation of the fascia lata. Preliminary report on 42 invasive vulvar carcinomas. *J Reprod Med* 1990;35(12):1130–4.
- Hacker NF, Leuchter RS, Berek JS, Castaldo TW, Lagasse LD. Radical vulvectomy and bilateral inguinal lymphadenectomy through separate groin incisions. *Obstet Gynecol* 1981;58(5):574–9.

26. Stehman F, Bundy B, Thomas G, Varia M, Okagaki T, Roberts J, et al. Groin dissection versus groin radiation in carcinoma of the vulva: a Gynecologic Oncology Group study. *Int J Radiat Oncol Biol Phys* 1992;24(2):389–96.
27. Koh WJ, Chiu M, Stelzer KJ, Greer BE, Mastras D, Comsia N, et al. Femoral vessel depth and the implication for groin node radiation. *Int J Radiat Oncol Biol Phys* 1993;27(3):969–74.
28. Katz A, Eifel PJ, Jhingran A, Levenback CF. The role of radiation therapy in preventing regional recurrences of invasive squamous cell carcinoma of the vulva. *Int J Radiat Oncol Biol Phys* 2003;57(2):409–18.
29. Petereit DG, Mehta MP, Buchler DA, Kinsella TJ. A retrospective review of nodal treatment for vulvar cancer. *Am J Clin Oncol* 1993;16(1):38–42.
30. Homesley HD, Bundy BN, Sedlis A, Adcock L. Radiation therapy versus pelvic node resection for carcinoma of the vulva with positive groin nodes. *Obstet Gynecol* 1986;68(6):733–40.
31. Origoni M, Sideri M, Garsia S, Carinelli SG, Ferrari AG. Prognostic value of pathological patterns of lymph node positivity in squamous cell carcinoma of the vulva stage III and IVA FIGO. *Gynecol Oncol* 1992;45(3):313–6.
32. Paladini D, Cross P, Lopes A, Monaghan J. Prognostic significance of lymph node variables in squamous cell cancer of the vulva. *Cancer* 1994;74(9):2491–6.
33. van der Velden J, van Lindert AC, Lammes FB, ten Kate FJ, Sie-Go DM, Oosting H, et al. Extracapsular growth of lymph node metastases in squamous cell cancer of the vulva. The impact on recurrence and survival. *Cancer* 1995;75(12):2885–90.
34. Hacker NF, Berek JS, Lagasse LD, Leuchter RS, Moore JG. Management of regional lymph nodes and their prognostic influence in vulvar cancer. *Obstet Gynecol* 1983;61(4):408–12.
35. Hyde SE, Valmadre S, Hacker NF, Schilthuis MS, van der Velden J. Squamous cell carcinoma of the vulva with bulky positive groin nodes – nodal debulking versus full groin dissection prior to radiation therapy. *Int J Gynecol Cancer* 2007;17(1):154–8.
36. Montana GS, Thomas GM, Moore DH, Saxer A, Mangan CE, Lentz SS, et al. Preoperative chemoradiation for carcinoma of the vulva with N2/N3 nodes: a Gynecologic Oncology Group Study. *Int J Radiat Oncol Biol Phys* 2000;48(4):1007–13.
37. Hacker NF, Berek JS, Juillard GJF, Lagasse LD. Preoperative radiation therapy for locally advanced vulvar cancer. *Cancer* 1984;54(10):2056–60.
38. Boronow RC, Hickman BT, Reagan MT, Smith RA, Steadham RE. Combined therapy as an alternative to exenteration for locally advanced vulvovaginal cancer. II. Results, complications and dosimetric and surgical considerations. *Am J Clin Oncol* 1987;10(2):171–81.
39. Moore DH, Thomas GM, Montana GS, Saxer A, Gallup DG, Olt G. Preoperative chemoradiation for advanced vulvar cancer: a phase II study of the Gynecologic Oncology Group. *Int J Radiat Oncol Biol Phys* 1998;42(1):79–85.
40. Lupi G, Raspagliesi F, Zucali R, Fontanelli R, Paladini D, Kenda R, et al. Combined preoperative chemoradiotherapy followed by radical surgery in locally advanced vulvar carcinoma. A pilot study. *Cancer* 1996;77(8):1472–8.
41. Landoni F, Maneo A, Zanetta G, Colombo A, Nava S, Placa F, et al. Concurrent preoperative chemotherapy with 5-fluorouracil and mitomycin C and radiotherapy (FUMIR) followed by limited surgery in locally advanced and recurrent vulvar carcinoma. *Gynecol Oncol* 1996;61(3):321–7.
42. Cunningham MJ, Goyer RP, Gibbons SK, Kredentser DC, Malfetano JH, Keys H. Primary radiation, cisplatin, and 5-fluorouracil for advanced squamous cell carcinoma of the vulva. *Gynecol Oncol* 1997;66(2):258–61.
43. Geisler JP, Manahan KJ, Buller RE. Neoadjuvant chemotherapy in vulvar cancer: avoiding primary exenteration. *Gynecol Oncol* 2006;100(1):53–7.
44. Faul CM, Mirmow D, Huang O, Gerszten K, Day R, Jones MW. Adjuvant radiation for vulvar carcinoma: improved local control. *Int J Radiation Oncol Biol Phys* 1997;38(2):381–9.
45. Verschraegen CF, Benjapibal M, Supakarapongkul W, Levy LB, Ross M, Atkinson EN, et al. Vulvar melanomas at the M.D. Anderson Cancer Center: 25 years later. *Int J Gynecol Cancer* 2001;11(5):359–64.
46. Trimble EL, Lewis JL Jr, Williams LL, Curtin JP, Chapman D, Woodruff JM, et al. Management of vulvar melanoma. *Gynecol Oncol* 1992;45(3):254–8.
47. Phillips GL, Bundy BN, Okagaki T, Kucera PR, Stehman FB. Malignant melanoma of the vulva treated by radical hemivulvectomy: a prospective study of the Gynecologic Oncology Group. *Cancer* 1994;73(10):2626–32.
48. Balch CM, Soong SJ, Bartolucci AA, Urist MM, Karakousis CP, Smith TJ, et al. Efficacy of an elective regional lymph node dissection of 1 to 4 mm thick melanomas for patients 60 years of age and younger. *Ann Surg* 1996;224(3):255–63.
49. Copeland LJ, Sneige N, Gershenson DM, McGuffee VB, Abdul-Karim F, Rutledge FN. Bartholin gland carcinoma. *Obstet Gynecol* 1986;67(6):794–801.
50. Fanning J, Lambert L, Hale TM, Morris PC, Schuerch C. Paget's disease of the vulva: prevalence of associated vulvar adenocarcinoma, invasive Paget's disease, and recurrence after surgical excision. *Am J Obstet Gynecol* 1999;180(1 Pt 1):24–7.