

## Popliteal artery entrapment syndrome presenting as acute limb ischemia in pregnancy

William Sellers, DO,<sup>a</sup> Melissa Obmann, DO,<sup>b</sup> Shivprasad Nikam, MD,<sup>b</sup> Boyoung Song, MD,<sup>b</sup> and David Mariner, MD,<sup>b</sup> Wilkes-Barre, Pa

### ABSTRACT

Popliteal artery entrapment syndrome typically causes calf claudication in young active adults. Acute limb ischemia from popliteal artery thrombosis, embolization, or aneurysmal degeneration is less common. Chronic compression, histologic changes, and predisposing factors, such as vigorous exercise or hypercoagulability, play a role in these cases. We present the case of a 32-year-old pregnant woman with acute limb ischemia found to have popliteal artery thrombosis as a result of popliteal artery entrapment syndrome. Although many imaging modalities are available, pregnancy creates a unique situation in which consideration of irradiation and exposure to contrast material is important in diagnosis and treatment. (*J Vasc Surg Cases and Innovative Techniques* 2017;3:232-5.)

The majority of patients with lower extremity ischemia have atherosclerotic occlusive disease. Nonatheromatous disease is often diagnosed late because of rarity, age, and lack of risk factors.<sup>1</sup> Delay in diagnosis results in critical limb ischemia and disability. It is of utmost importance to keep nonatheromatous diseases in mind, especially in young patients with ischemia.<sup>2</sup> Popliteal artery entrapment syndrome (PAES) is an uncommon cause of lower extremity claudication most often seen in athletes. We present a case of a 32-year-old pregnant woman with acute limb ischemia found to have popliteal artery thrombosis as a result of PAES. To our knowledge, this is only the second reported case in the literature.<sup>2</sup> We review PAES and the diagnostic as well as therapeutic challenges associated with presentation in pregnancy. The patient consented to publication of this report.

### CASE REPORT

A 32-year-old pregnant woman (G5P4), at 12 weeks of gestation, presented to an outside hospital for evaluation of right foot pain that started 6 days before. Her pain progressively

worsened and ascended to involve her lower leg. Lower extremity venous duplex ultrasound was negative for deep venous thrombosis; however, a thrombus was noted in the right popliteal artery. She was transferred emergently to our institution for evaluation. She was otherwise healthy and denied any history of smoking, claudication, or vasculopathy. She denied any history of similar symptoms, including during her previous pregnancies and while exercising. The right foot was cool and pale with delayed capillary refill and no palpable pedal pulses with only monophasic Doppler signals. The left foot was warm and well perfused with palpable pedal pulses. Ankle-branchial index was 0.56 on the right and 0.98 on the left. Arterial duplex ultrasound revealed an acute-on-chronic mobile thrombus within the right popliteal artery.

She was admitted, and a continuous heparin infusion was started. The obstetrics service was consulted for fetal monitoring. Findings of echocardiography and a thorough hypercoagulability workup were normal. As the patient was a young, healthy nonsmoker, without atherosclerotic disease or risk factors, PAES was suspected. After discussion with our radiologist, magnetic resonance imaging (MRI) with time of flight imaging was performed. Her right popliteal artery was found to be medial to the medial head of the gastrocnemius with 70% focal stenosis (Fig 1).

The patient was diagnosed with PAES and was taken to the operating room for repair of the right popliteal artery. A posterior exposure was used. The artery had a normal course and appearance but was partially encased by a large accessory slip of muscle from the medial head of the gastrocnemius, consistent with type III PAES. There was a large tapered thrombus within the popliteal artery and tibioperoneal trunk. The patient underwent right medial accessory gastrocnemius myotomy, longitudinal arteriotomy, balloon thromboembolectomy, and patch angioplasty with bovine pericardium (Fig 2).

Postoperatively, the patient recovered well and was neurologically intact with palpable pedal pulses. She was seen by the obstetrics service and underwent fetal heart rate monitoring. She

---

From the Department of General Surgery<sup>a</sup> and Department of Endovascular and Vascular Surgery,<sup>b</sup> Geisinger Wyoming Valley Medical Center.

Author conflict of interest: none.

Presented as a podium presentation at the Twenty-ninth Annual Meeting of the Eastern Vascular Society, Baltimore, Md, September 24-26, 2015.

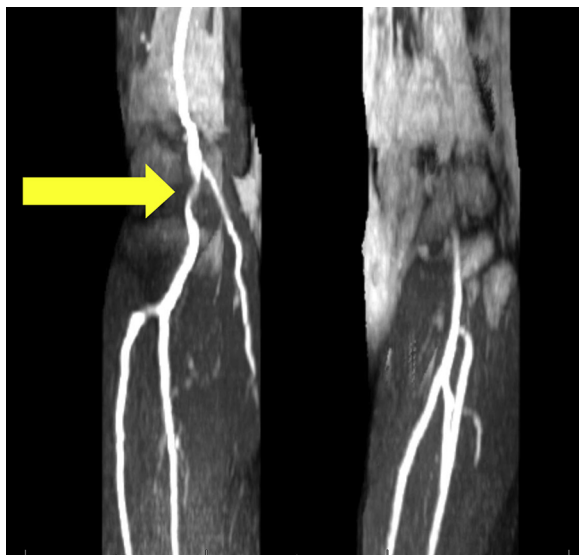Correspondence: William Sellers, DO, Department of General Surgery, Geisinger Wyoming Valley Medical Center, 1000 E Mountain Blvd, Wilkes-Barre, PA 18702 (e-mail: [wjsellers@geisinger.edu](mailto:wjsellers@geisinger.edu)).

The editors and reviewers of this article have no relevant financial relationships to disclose per the Journal policy that requires reviewers to decline review of any manuscript for which they may have a conflict of interest.

2468-4287

© 2017 Published by Elsevier Inc, on behalf of Society for Vascular Surgery. This is an open access article under the CC BY-NC-ND license (<http://creativecommons.org/licenses/by-nc-nd/4.0/>).

<https://doi.org/10.1016/j.jvscit.2017.09.006>



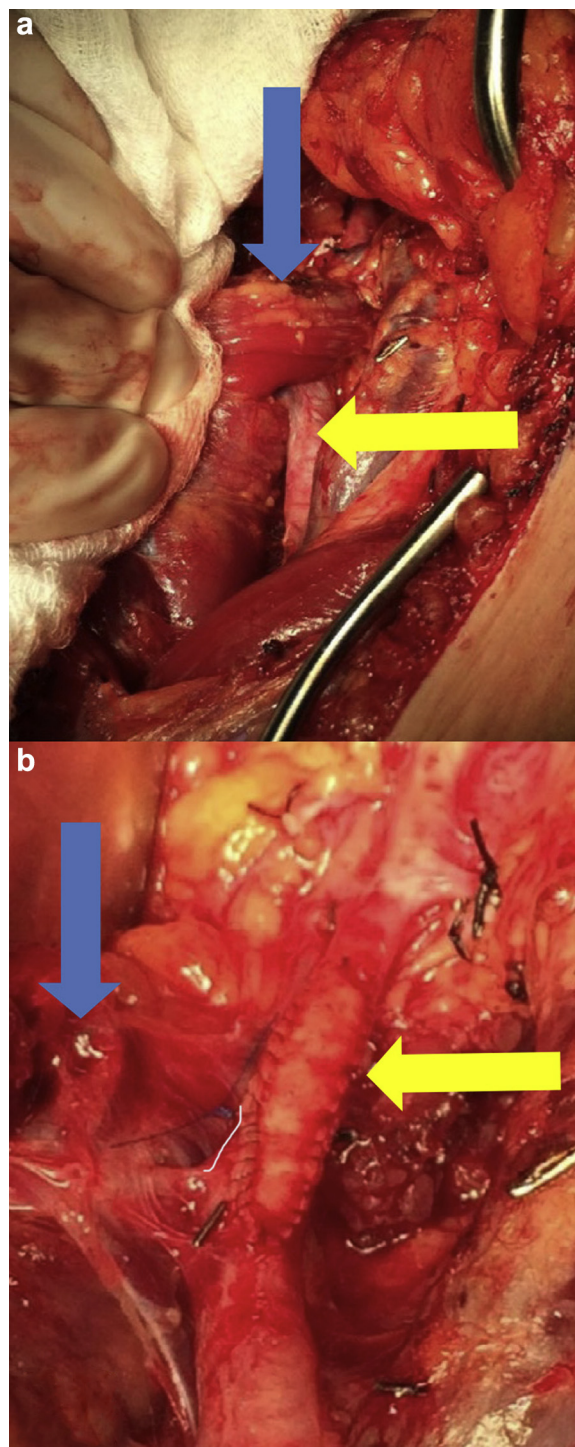
**Fig 1.** Magnetic resonance imaging (MRI) with time of flight imaging showing 70% focal stenosis of right popliteal artery (arrow).

was prescribed 81 mg aspirin daily and was discharged home on postoperative day 3. At her follow-up visit, she had a normal gait and palpable pedal pulses, and her foot was warm and well perfused. The ankle-branchial index was 0.9 on the right and 1.06 on the left, and duplex ultrasound confirmed a patent right popliteal artery. Perhaps most important, several months later she gave birth to a healthy baby boy. After her pregnancy, magnetic resonance angiography with contrast enhancement was performed and was negative for contralateral popliteal entrapment.

## DISCUSSION

The embryologic origin of PAES plays a critical role in the pathophysiologic process. The medial head of the gastrocnemius arises from the posterior fibula and lateral tibia and migrates across the popliteal fossa to attach on the medial femoral condyle. Simultaneously, the popliteal artery forms superficial to the popliteus muscle.<sup>3</sup> Variation in this process results in six different subtypes (Fig 3).<sup>4</sup> Anatomically first described by a medical student dissecting an amputated leg in 1879, PAES was not clinically described until 1958 by Hamming.

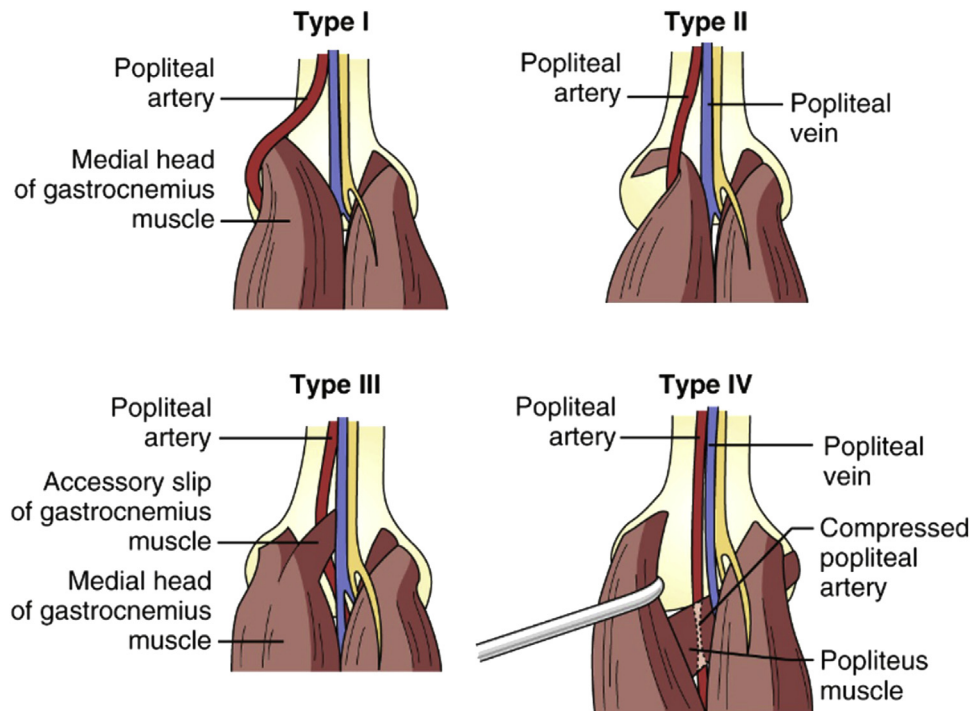
PAES is commonly seen in young, healthy athletes but is also seen in drivers of trucks, buses, and military vehicles. All of these activities require repeated forceful contraction of the calf, which results in hypertrophy.<sup>2</sup> Early in the clinical course, the artery is patent except during muscle contraction. Symptoms are sudden in onset during exercise and include paresthesia, blanching, coldness, and cramps, which resolve with a change of position. Later, patients will report leg swelling, aching pain, pain at rest, and fatigue. Examination findings similarly change throughout the course of the disease. Provocative tests, such as lower extremity hyperextension



**Fig 2. A,** Right popliteal artery (yellow arrow) entrapped by accessory slip of the medial head of the gastrocnemius (blue arrow). **B,** Bovine pericardial patch angioplasty of right popliteal artery (yellow arrow) with divided gastrocnemius muscle (blue arrow).

and contraction, may lead to a decrease in distal pulse and aid in diagnosis.<sup>1</sup>

Duplex ultrasound is a noninvasive, quick, and inexpensive test that is ideally suited for examination of the popliteal artery. It is important to screen the opposite



**Fig 3.** Types of popliteal artery entrapment syndrome (PAES). **I**, The artery develops before migration, pushing the artery medially. **II**, Migration of the gastrocnemius is arrested. **III**, The gastrocnemius remains posterior to the artery or the artery originates from within the muscle. **IV**, The artery is deep to the popliteus. **V**, Any of the previous types accompanied by venous entrapment (not illustrated). **VI**, Functional entrapment causing compression without anatomic abnormality (not illustrated).

limb, as PAES is bilateral in two-thirds of cases. Ultrasound, however, cannot analyze soft tissue structures and has a high false-positive rate (72%). Traditionally, angiography was the “gold standard,” but today, computed tomography and MRI are superior at visualizing the position of the artery in relation to the muscle.<sup>5</sup> Gadolinium contrast agent is water soluble and can therefore cross the placenta into the fetal circulation with potential for teratogenic effects. MRI with time of flight angiography was used in this case to determine any flow limitation without the use of contrast material.

Surgery is indicated for symptomatic PAES to establish normal arterial flow. Early in the clinical course, myotomy alone may suffice; but later, the artery can become occluded, stenotic, or aneurysmal, requiring vascular reconstruction. A posterior approach with an S- or Z-shaped incision enables complete exposure of the popliteal artery and its surrounding structures. A medial approach offers better exposure of the superficial femoral and tibial arteries, but it cannot identify all the structures around the popliteal artery. This approach has a higher risk of incomplete myotomy but is less morbid and offers quicker return to athletic activities.<sup>5</sup> After discussion with the obstetrics service, the prone position was determined to be a safe option because at 12 weeks of gestation, the uterus remains in the pelvis and is not an intra-abdominal organ. Later in pregnancy,

the prone position would not be feasible, and femoral-popliteal bypass could be performed through a medial approach.

The presentation of acute limb ischemia in pregnancy requires numerous special considerations. The risk of radiation exposure to the fetus makes computed tomography and angiography undesirable choices for imaging. Concerns also exist about iodinated and gadolinium-based contrast agents in pregnancy, although no conclusive data exist that there is any risk to the fetus. Tissue plasminogen activator and warfarin must be avoided, but enoxaparin and heparin can be safely administered. To avoid the teratogenic effects of many inhalational agents, our patient underwent total intravenous anesthesia, a technique whereby induction as well as maintenance anesthesia is carried out with intravenous agents only. Furthermore, surgery could not be delayed until after pregnancy. Given the progressive nature of her symptoms in the setting of her popliteal thrombosis, there was immediate concern that the thrombus would progress to involve her tibial vessels. Finally, this patient had no history of exertional calf pain or claudication and normal findings on hypercoagulability workup. One may deduce that the hypercoagulable state of her pregnancy and possibly dehydration with some recent increase in activity may have precipitated the onset of her presentation. We theorize that pregnancy may itself be a risk factor for PAES.

## CONCLUSIONS

PAES is a rare cause of lower extremity ischemia that most commonly presents in young athletic patients. Variation in the embryologic development of the structures in the popliteal fossa can lead to six different types of PAES. Our patient was found to have an abnormal slip of the gastrocnemius that was encasing the popliteal artery, or a type III entrapment. PAES in pregnancy invokes numerous diagnostic and therapeutic considerations as discussed. We theorize that her pregnancy led to a hypercoagulable state and that pregnancy itself may be a risk factor for PAES. Ultimately, it is crucial to always consider PAES and other nonatheromatous causes in evaluating young, otherwise healthy patients with lower extremity ischemia.

## REFERENCES

1. Levien LJ, Veller MG. Popliteal artery entrapment syndrome: more common than previously recognized. *J Vasc Surg* 1999;30:587-98.
2. Bustabad MR, Ysa A, Pérez E, Merino J, Bardón F, Vela P, et al. Popliteal artery entrapment: eight years experience. *EJVES Extra* 2006;12:43-51.
3. Di Marzo L, Cavallaro A. Popliteal vascular entrapment. *World J Surg* 2005;29:S43-5.
4. Forbes TL. Nonatheromatous popliteal artery disease. In: Cronenwett JL, Johnston W, editors. *Rutherford's vascular surgery*. 7th ed. Philadelphia: Saunders Elsevier; 2010. p. 1721-7.
5. Sinha S, Houghton J, Holt PJ, Thompson MM, Loftus IM, Hinchliffe RJ. Popliteal entrapment syndrome. *J Vasc Surg* 2012;55:252-62.e30.

Submitted Mar 21, 2017; accepted Sep 17, 2017.